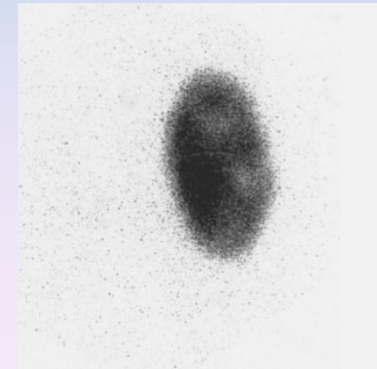
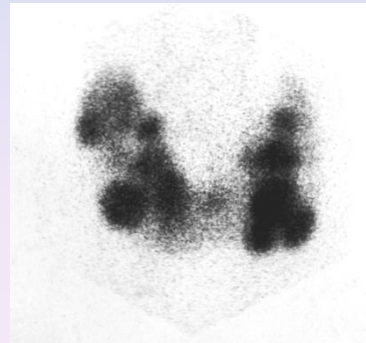
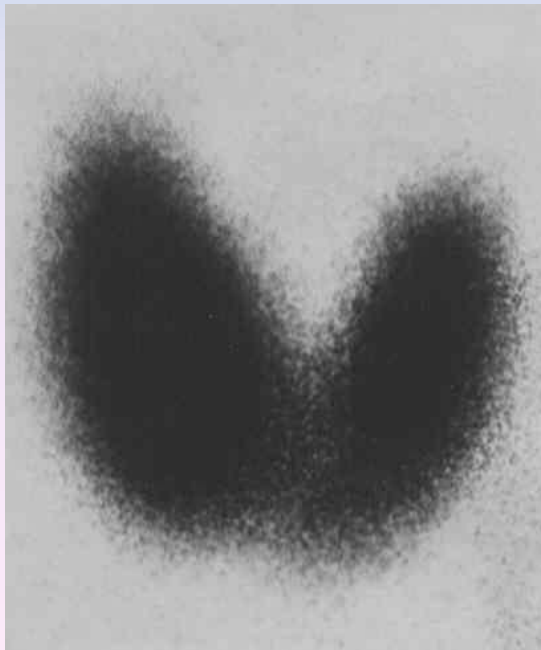
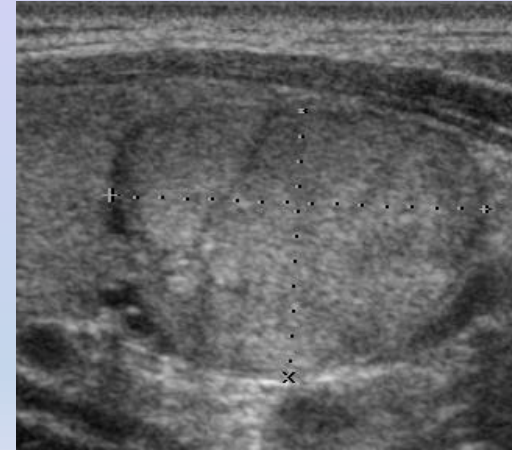
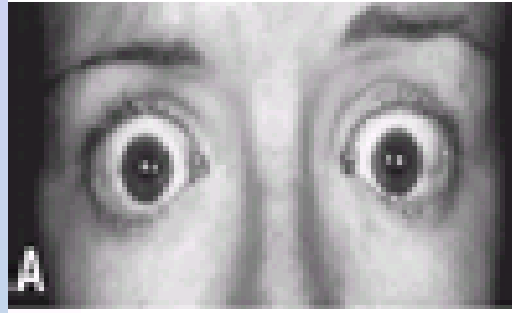
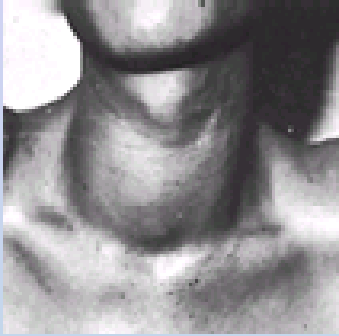

Hyperthyroidism and thyrotoxicosis



Assoc. prof. V. Marković, MD, PhD

Assoc. prof. A. Punda, MD, PhD

A. Barić, MD, nucl. med. spec.

Hyperthyroidism- Thyrotoxicosis

Hyperthyroidism- elevated serum levels of thyroid hormones caused by overproduction of thyroid hormones

Thyrotoxicosis: elevated serum level of thyroid hormones/ excessive amount of circulating thyroid hormone

Hyperthyreoidism includes thyreotoxycosis

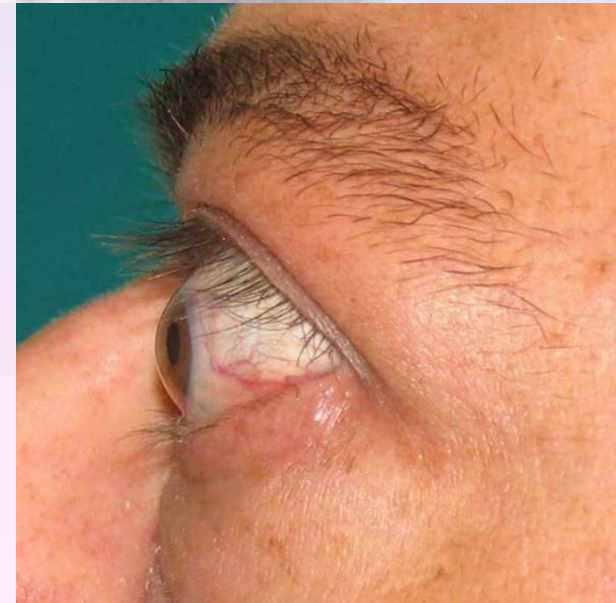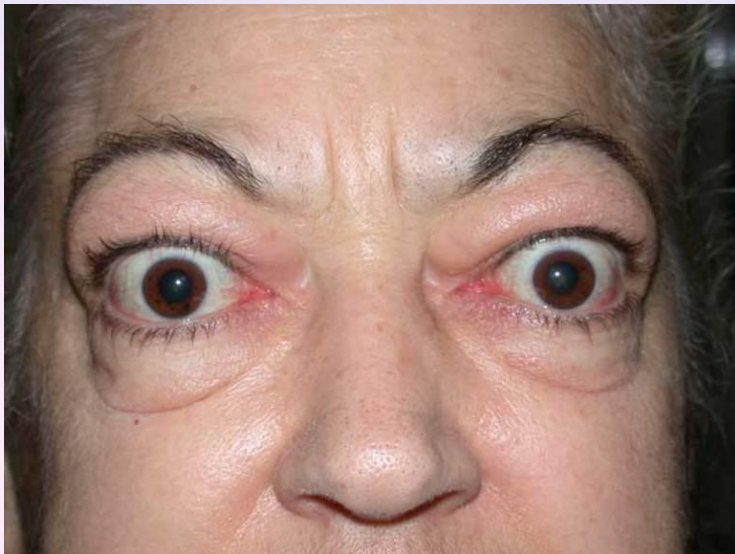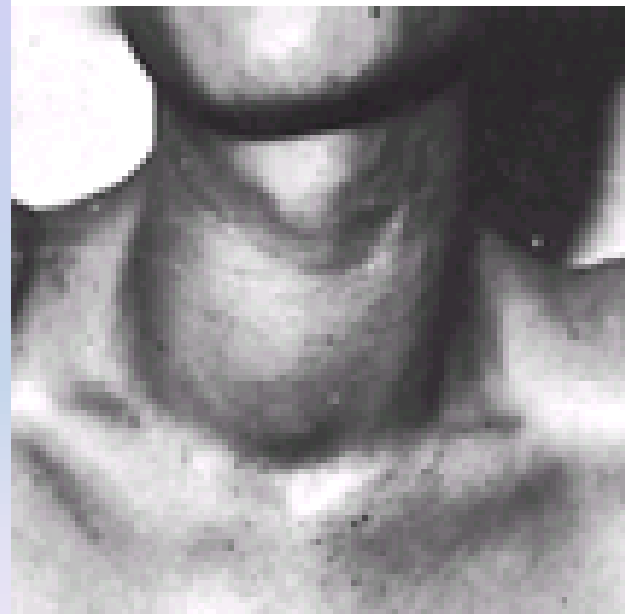
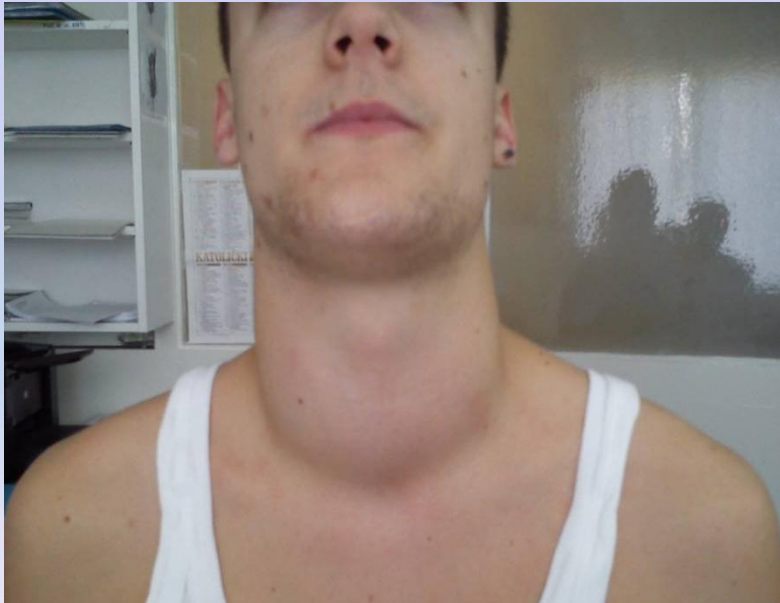
but

Thyrotoxicosis is not exclusively caused by hyperthyroidism

Classification of thyrotoxicosis

| Hyperthyroidism | Thyrotoxicosis without hyperthyroidism |
|---------------------------|----------------------------------------|
| Mb Basedow-Graves | Thyrotoxicosis factitia |
| Multinodular toxic goiter | Subacute thyroiditis (painfull) |
| Toxic adenoma | Subacute thyroiditis (painless) |
| Elevated TSH levels | Ectopic thyroid tissue |
| Trophoblastic tumors | |
| Iod-Basedow | |

Diffuse toxic goiter (Mb Basedow, Graves)



Diffuse toxic goiter

Mb. Graves-Basedow

Epidemiology and etiology

Diffuse toxic goiter (Mb. Graves-Basedow) is an autoimmune, multisystemic disease, which includes the thyroid gland, infiltrative ophthalmopathy, dermopathy and acropathy.

World wide prevalence is about 0,4-2% in women, 0,1% in men, includes 60-90% of hyperthyroidism cases*.

It is complex disease with predominant genetic component.&

Sex hormones, stress.

Disease is caused by TSH receptor stimulating antibodies/ TSH stimulating antibodies (TSAb), in 80-100% patients.

*Taunbridge WMG, Vanderpump MPJ. Population screening for autoimmune thyroid disease. *Endocrinol Metab Clin North Am.* 2000;29:239-253.

&Brix TH, Kyvik KO, Christensen K, et al. Evidence for a major role of heredity in Graves' disease: a population based study of two Danish twin cohorts. *J Clin Endocrinol Metab.* 2001;86:930.

Diffuse toxic goiter- complex disease with predominant genetic component

Genetic predisposition :

-If one of **monozygotic twins** has a diffuse toxic goiter incidence in the other is 35%, while in a case of **dizygotic twins** incidence is 3-6%

-Incidence in the general population is 0,6%, but in brothers/sisters of patients with diffuse toxic goiter incidence is 5,3%

Sex hormones

- it is more common in **women** (5-10x), and after puberty

Stress- precipitating factor

TSH receptor antibodies

Mb. Basedow is caused by circulating TSH receptor antibodies (Thybia), in 80-100% cases.

Source: B-lymphocytes in thyroid

Evidence:

-direct: detection of human antibodies in mice serum after transplantation of thyroid tissue from patients with Mb. Basedow

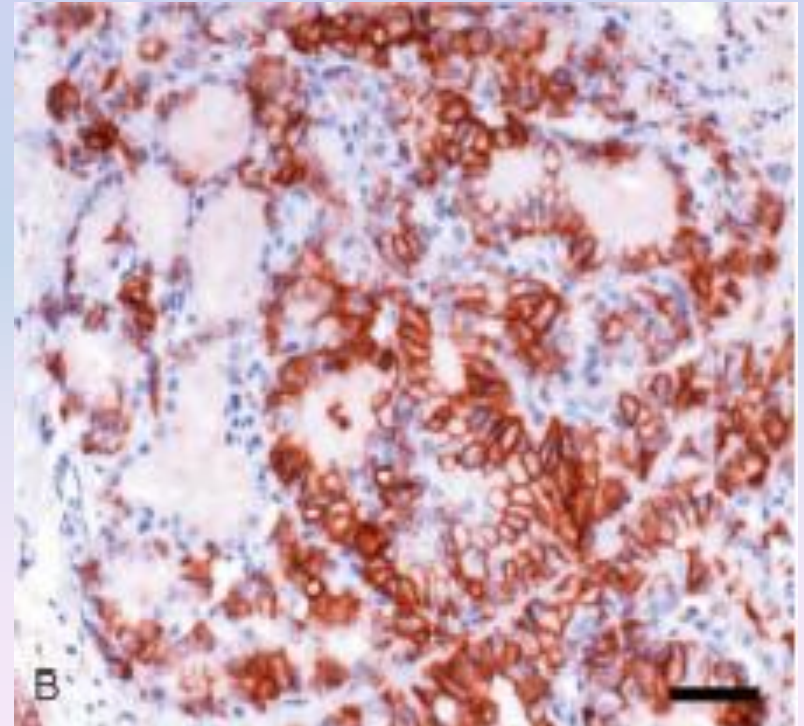
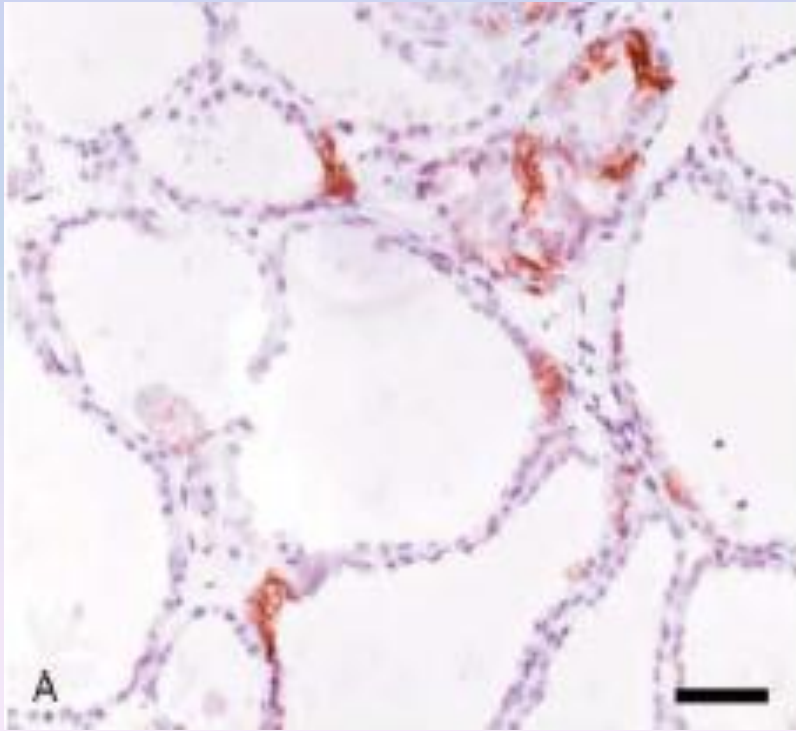
-indirect: decreased level of serum antibodies after thyrostatic therapy, surgical treatment or radioiodine therapy

Function: same as TSH: stimulation of iodine accumulation in thyroid, hormones syntesis and release, follicular cell growth

Histology and pathology

- Diffuse toxic goitre: hypertrophy and hyperplasia of follicular cells, they become high and cylindrical, reduction of colloid and increased parenchymal cellularity
- Thyreostatic therapy leads to partial involution of hypertrophic gland: some glands turn back to normal thyroid histology, while part of them remain hyperplastic

Histology



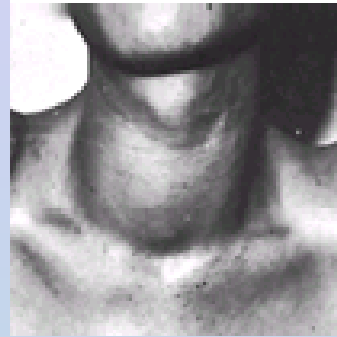
(A) Normal thyroid histology

(B) Thyroid histology in Mb. Basedow

Main difference- size of thyroid follicles.

Diffuse toxic goitre- three main clinical manifestations:

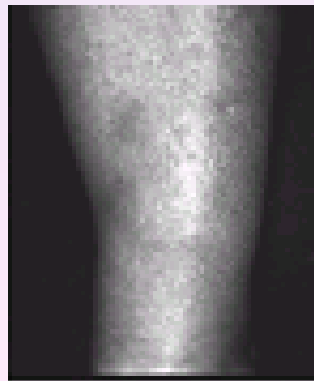- hyperthyroidism with diffuse goitre



- ophthalmopathy

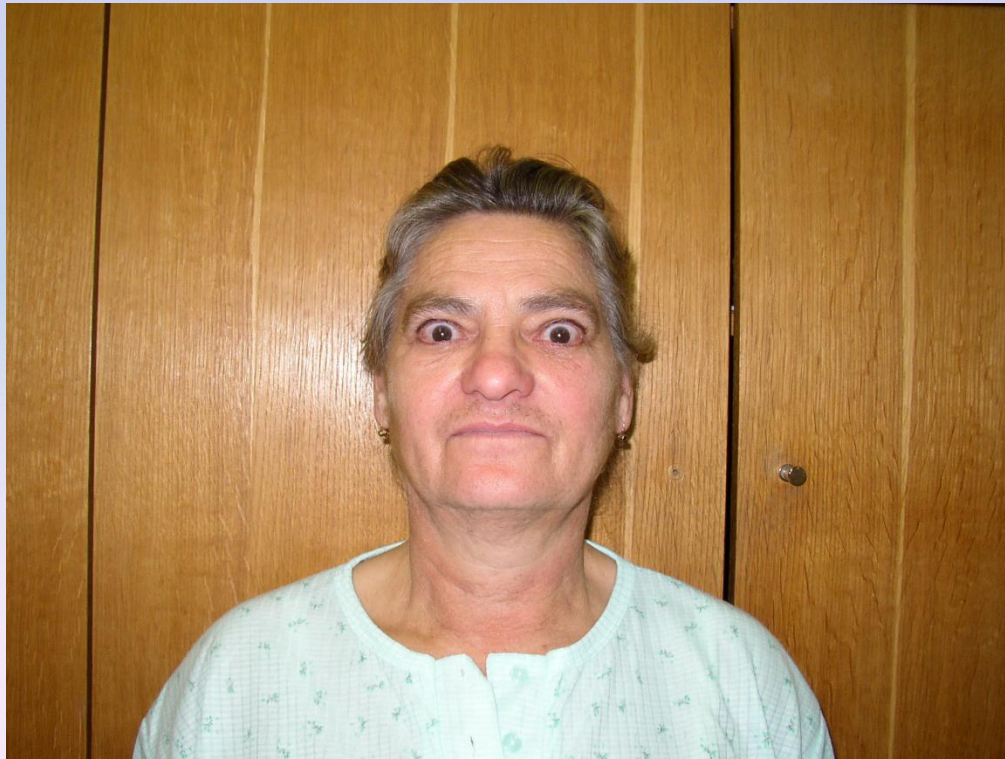


- dermatopathy, acropachy



Diffuse toxic goitre, Mb Basedow, Mb Graves

Basedow 1840'th



Thyroid-associated orbitopathy (TAO)

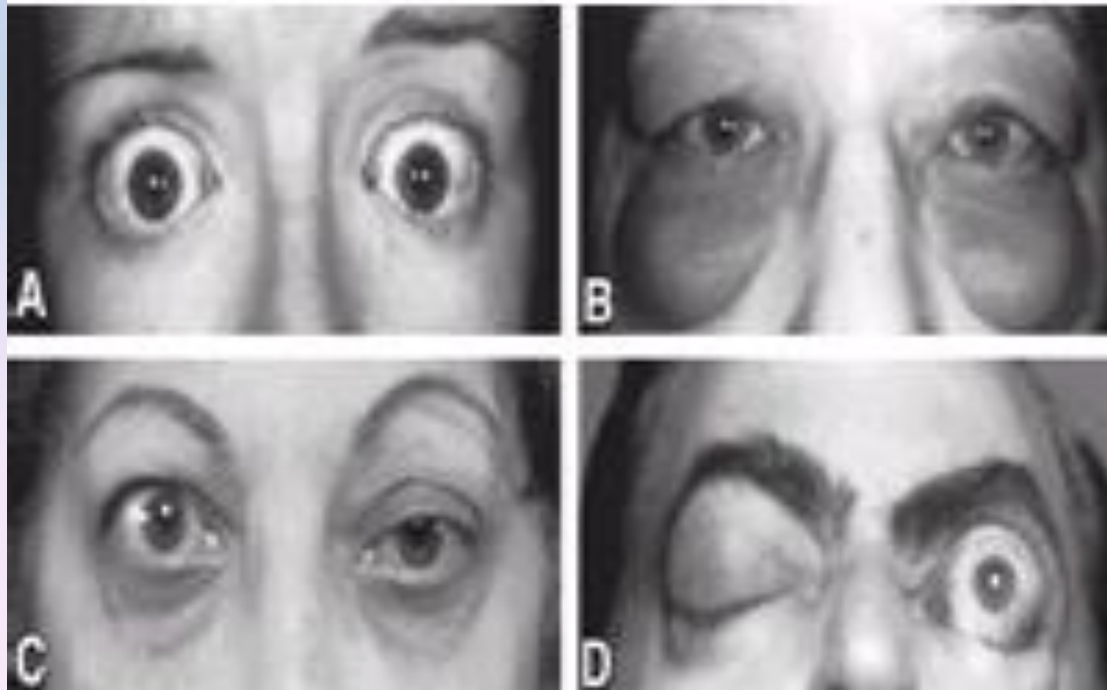
1. upper lid retraction, convergency weakness
2. swollen eyelids
3. eyeball protrusion
4. double vision (ocular muscle paresis)
5. corneal ulceration
6. pressure and stretching of the optic nerve- vision loss

Von Graefe's sign (lid lag sign- lagging of the upper eyelid on downward rotation of the eye)

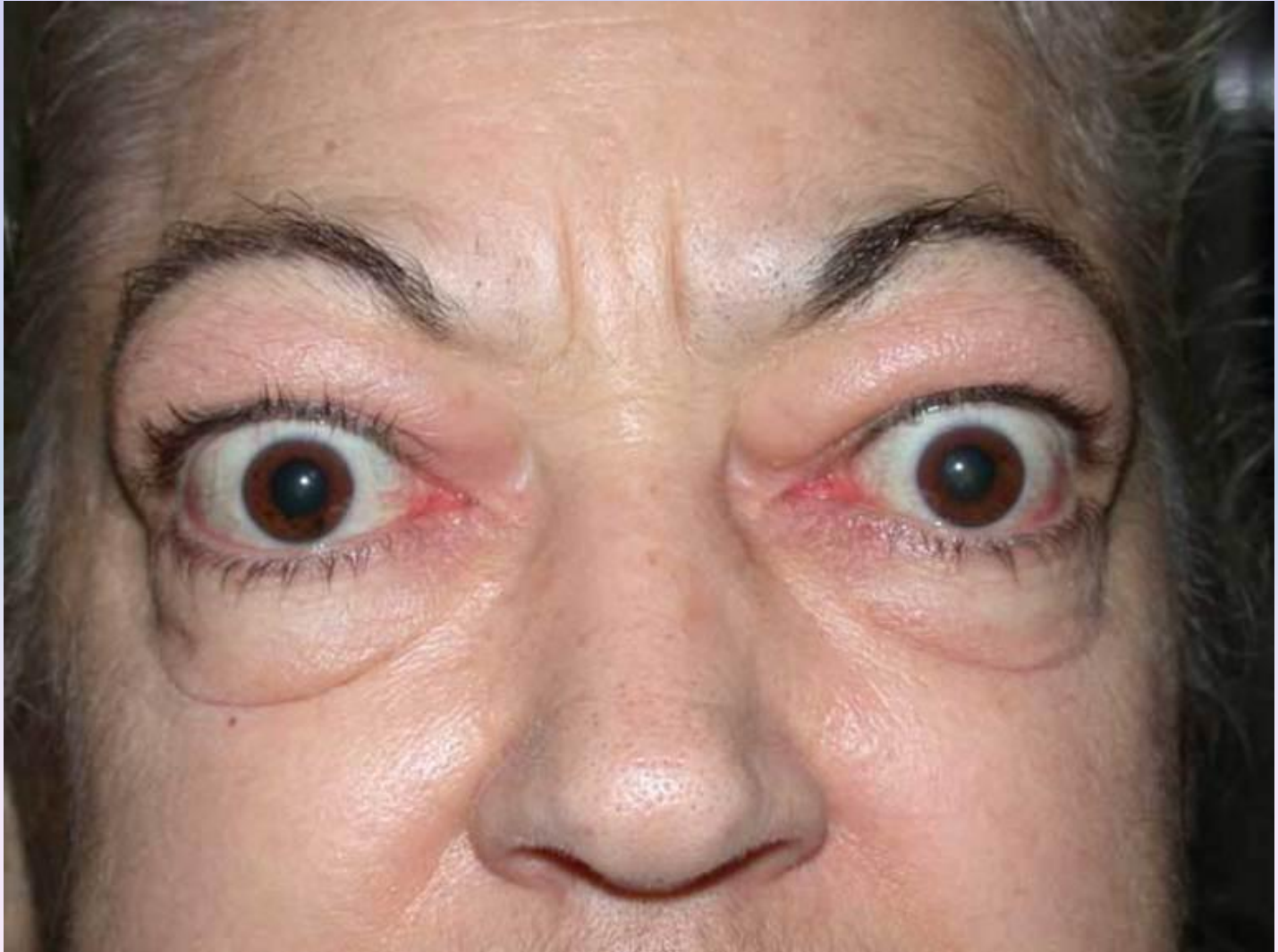Stellwag's sign (rare blinking)

Ophthalmopathy

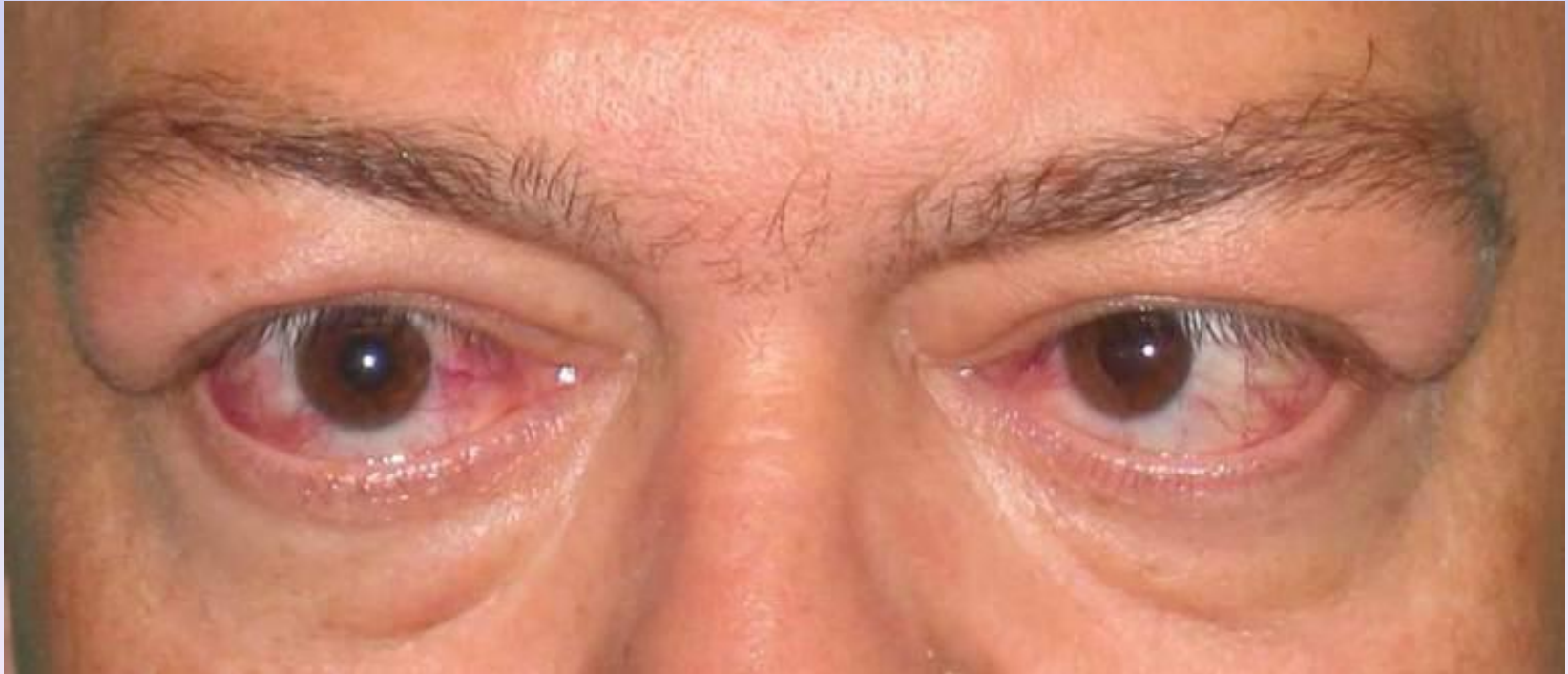Half of patients have no clinical signs of ophthalmopathy, 1/3 of them have mild clinical manifestations while 3-4% have severe condition in which specific treatment is necessary



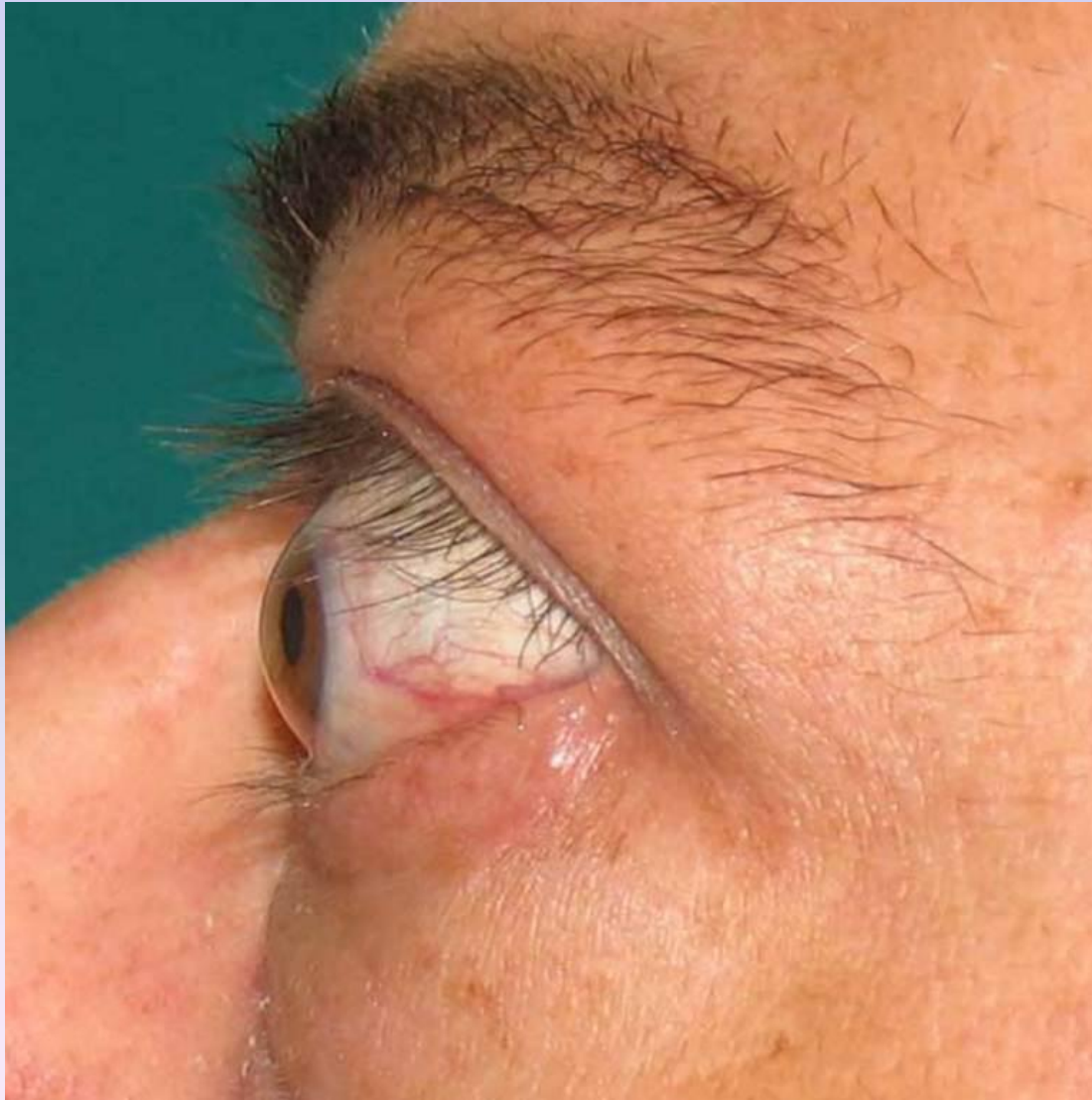A: Bilateral exophthalmos with upper lid retraction. B: Severe periorbital edema. C: Unilateral exophthalmos. D: Spontaneous globe subluxation of the proptotic left eye.



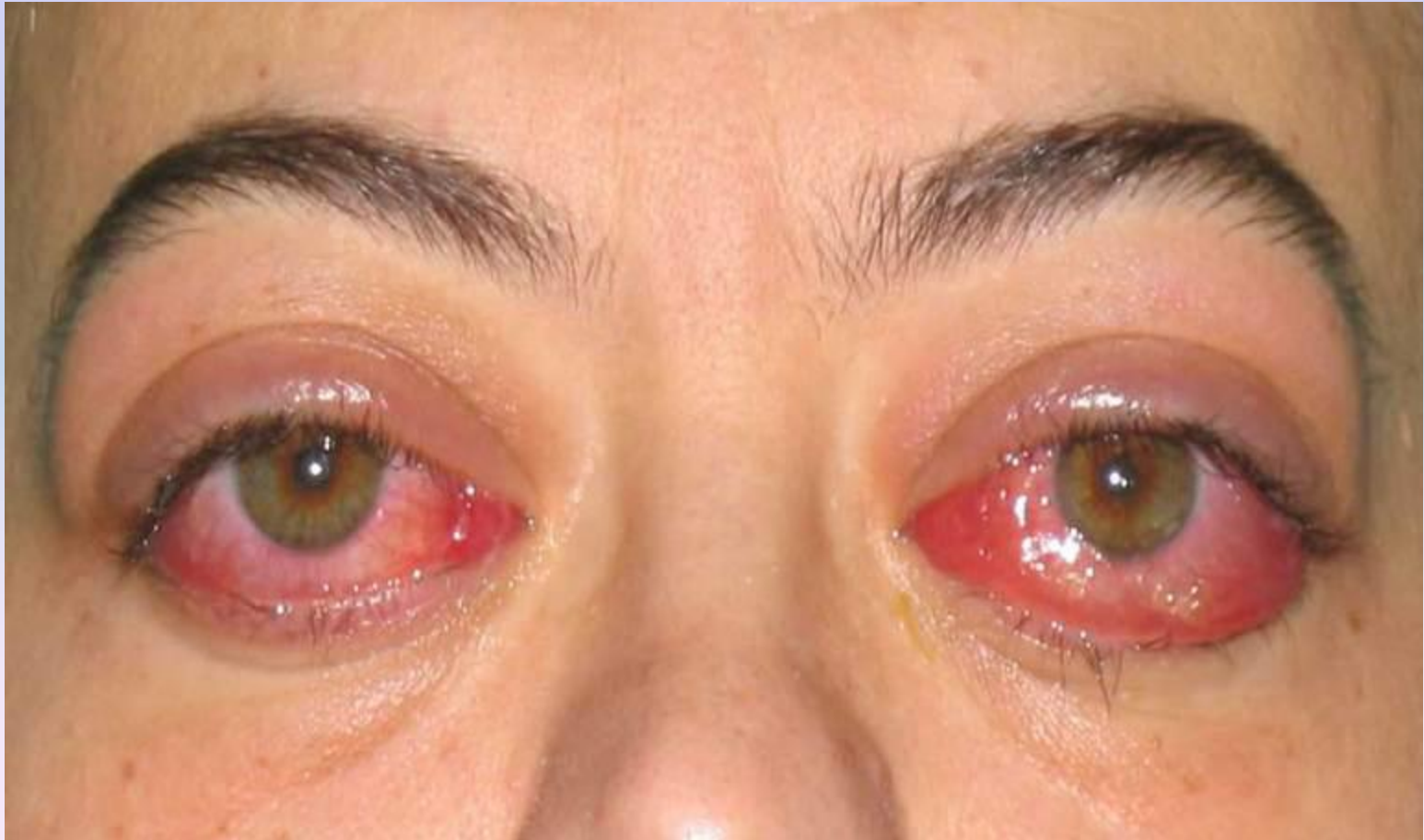Moderate-to-severe Graves' ophthalmopathy: periorbital edema, conjunctival injection, proptosis, lid retraction.



Moderate-to-severe Graves' ophthalmopathy : periorbital edema, conjunctival injection, strabismus of the left eye.

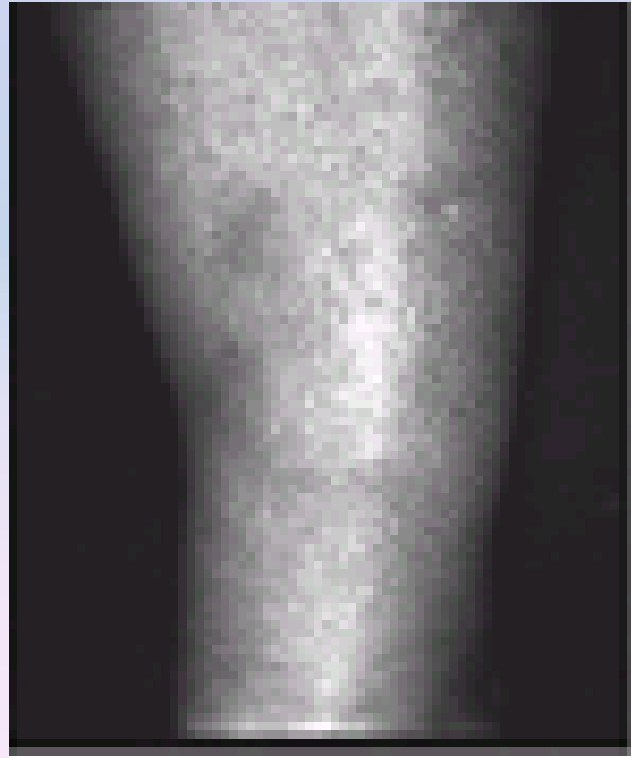
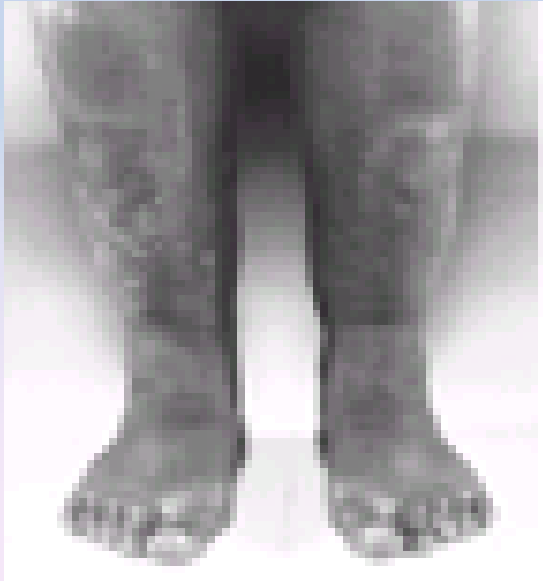
Moderate-to-severe Graves' ophthalmopathy: proptosis, upper eyelid retraction, conjunctival erythema.

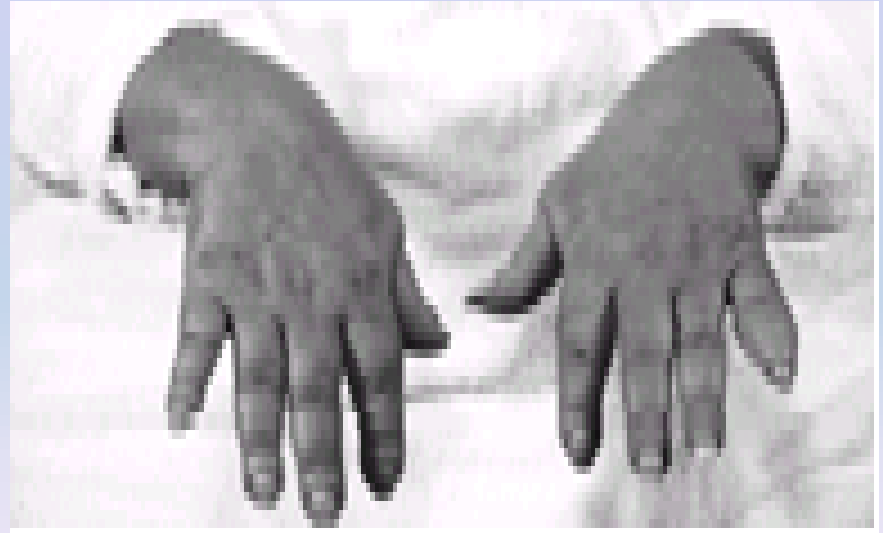
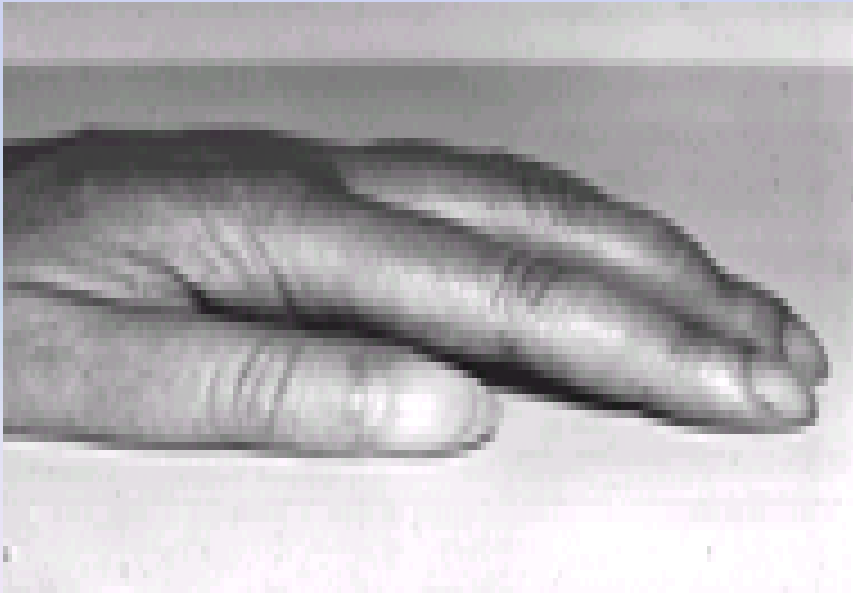


Severe Graves' ophthalmopathy: conjunctival erythema, proptosis, periorbital edema, two corneal ulcerations on the left eye.

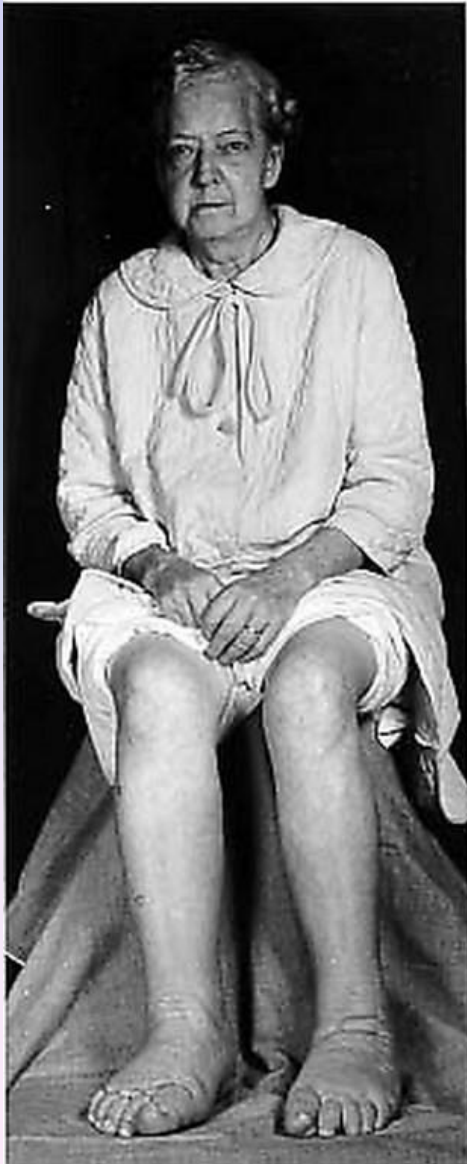Localised edema (most commonly in pretibial area) 4%



Thyroid acropachy 1%



Clubbing in the fingers and soft tissue swelling.
On the right picture changes are presented asymmetrically.
(subperiosteal new bone formation)



Remarkable "pretibial myxedema", also present on feet and hands, of a patient with Graves' disease and exophthalmos.

Clinical presentation:

- * hyperkinetic syndrome

tachycardia, excessive sweating, nervousness, insomnia, weight loss – despite an increased appetite, hyperkinetic movements, heat intolerance, hair loosening, tremor, frequent and loose stools

- * enlarged thyroid gland (goitre)

- * ophthalmopathy, pretibial edema

The frequency of symptoms

- nervousness (80-99%)
- excessive sweating (50-91%)
- palpitations (63-89%)
- heat intolerance (41-89%)
- fatigue, weakness (44-88%)
- dyspnoea on effort (66-81%)
- weight loss (52-85%)
- increased appetite (11-65%)
- frequent stools (12-23%)

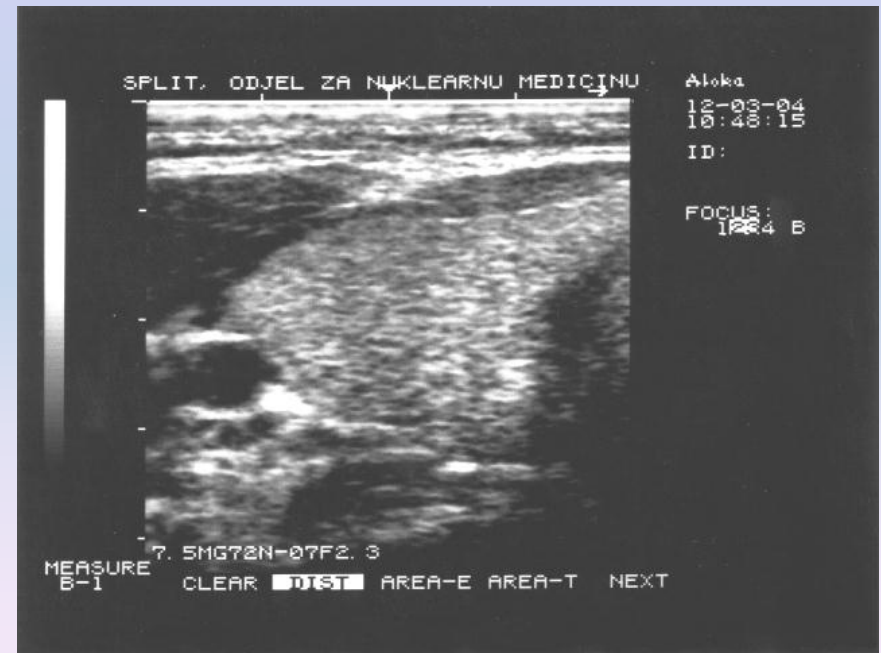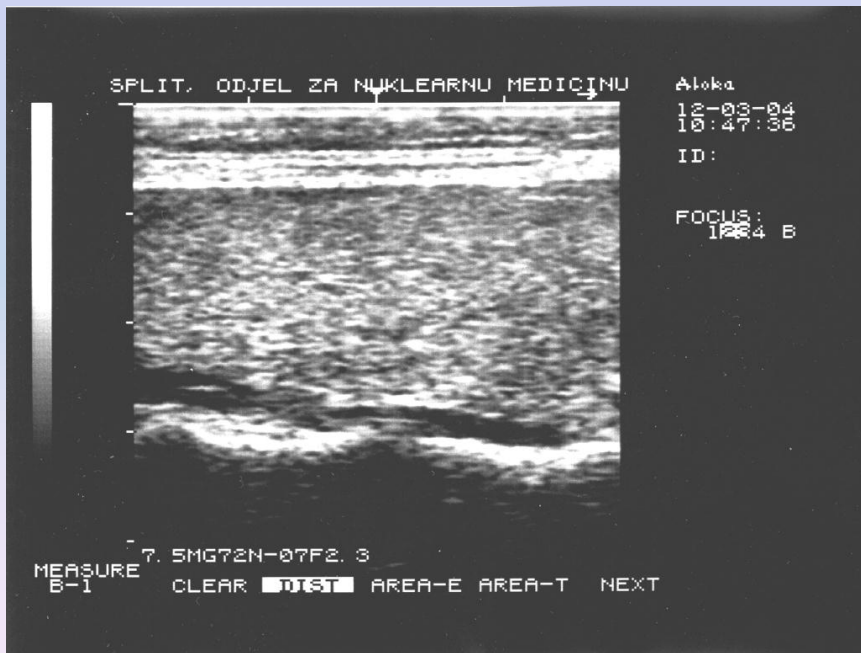The frequency of symptoms

- tachycardia (58-100%)
- goitre (37-100%)
- tremor (40-97%)
- warm and moist skin (76%)
- thyroid murmur (28-77%)
- lid retraction and lagging (38-62%)
- atrial fibrillation (10%)
- splenomegaly (10%)

Diagnosis

- Anamnesis
- Clinical presentation
- TSH ↓, T4 (FT4) ↑, T3 (FT3) ↑
- accumulation of I-131 in thyroid ↑
- positive TSH receptor antibody (>85%)
- ultrasonography

US presentation of the thyroid gland

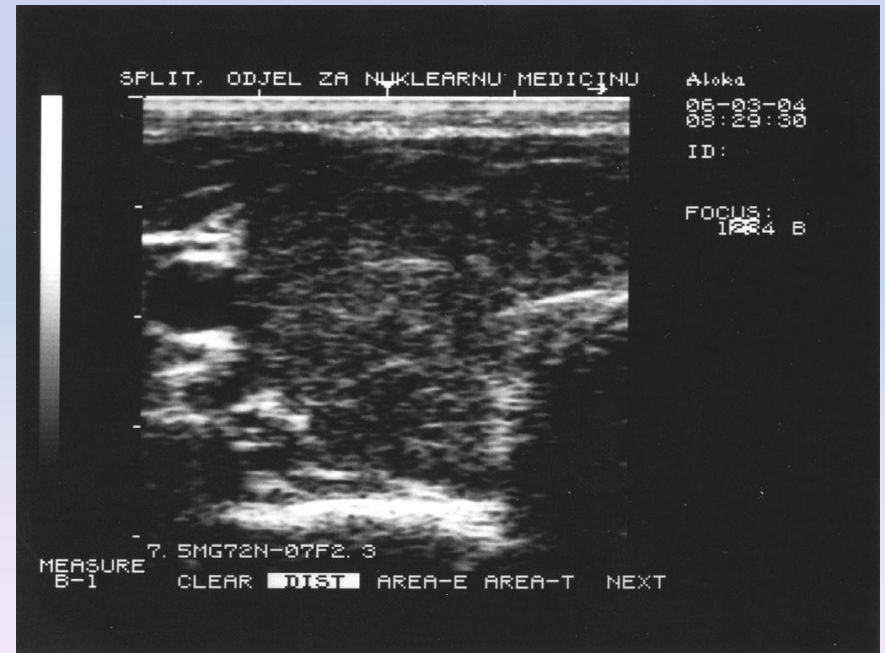
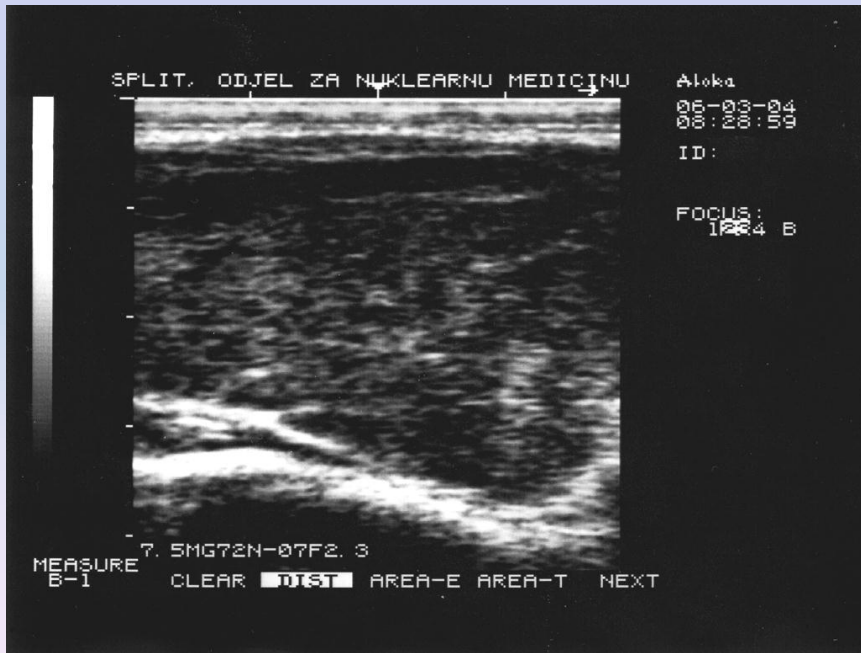
Normal thyroid ultrasound (normoechogenicity), left: longitudinal section, right: cross-section.

Thyroid ultrasound

- Untreated diffuse toxic goitre: gland structure is more permeable for US waves because it has higher cell proliferation and relatively empty follicles (lower difference in acoustic impedance between structures)- so the lower number of the waves are reflected back to the US probe
- It is presented as hypoechogenic

Thyroid ultrasound

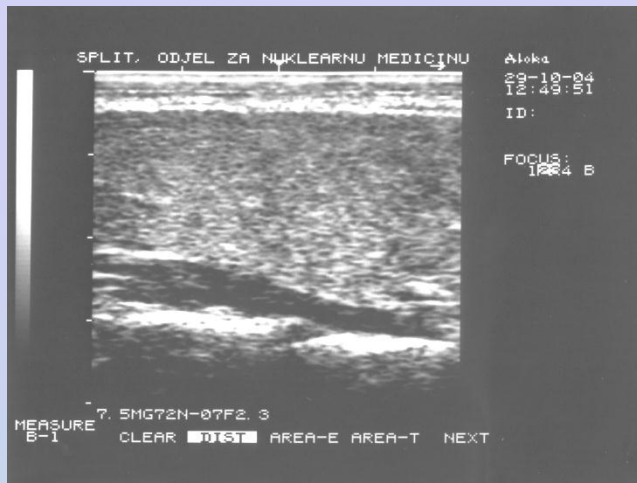

Thyroid is hypoechoogenic in Mb. Basedow

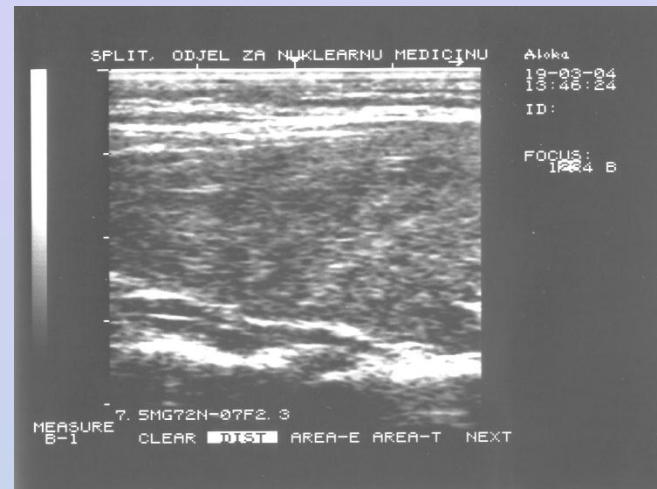Left: longitudinal section, right: cross-section.

During thyrostatic therapy US picture of the gland is being changed- mostly it will be transformed as in normal condition, while some glands remain hypoechogenic.

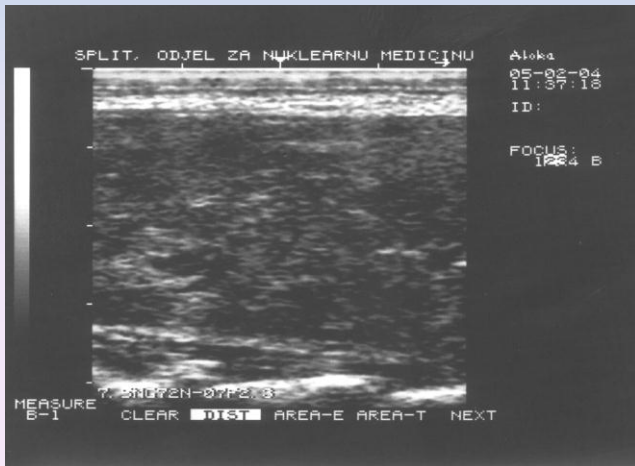
US apperance of the thyroid reflects hystology and functional status of the gland



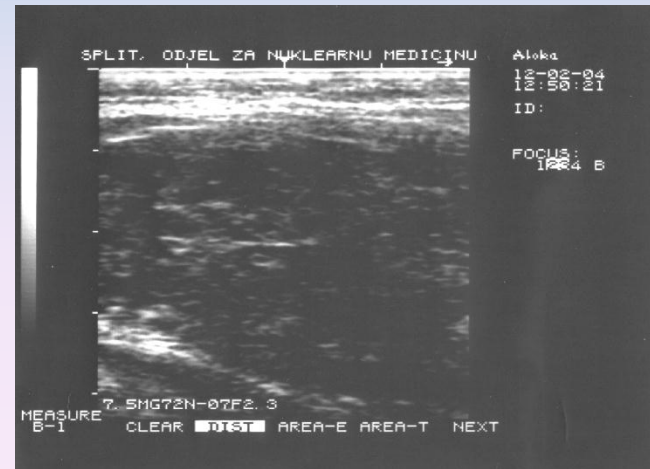
a) Normoechogenic thyroid



b) Slightly hypoechoic thyroid



c) Moderately hypoechoic thyroid



c) Markedly hypoechoic thyroid

Differential diagnosis

- **Psychoneurologic disorders:** nervousness, tremor, palpitations, sweating, fatigue.
- **Chronic obstructive pulmonary disease (COPD):** fatigue, warm skin, hyperpigmentation
- **Pheochromocytoma:** heat intolerance, hot flashes, flushings, tachychardia.
- **Diabetes mellitus:** fatigue, warm skin, weight loss.
- **Progressive muscular atrophy, polymyositis:** symptoms similar to thyrotoxic myopathy.
- **Other hyperthyreoidism and thyrotoxicosis**

Other hyperthyroidism and thyrotoxicosis

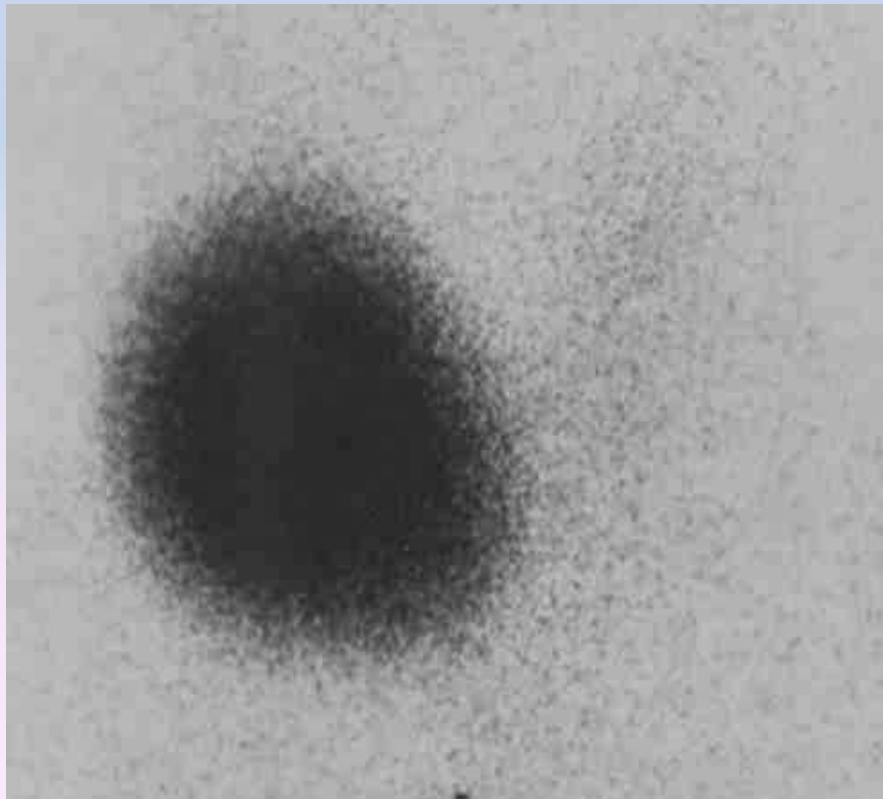
Common cause:

- toxic adenoma and toxic multinodular goiter
- subacute thyroiditis: painful or painless (silent)
- Iodbasedow
- Exogenous thyrotoxicosis (thyroid hormone intake)

Rare cause:

- pituitary adenoma, pituitary thyroid hormone resistance (PRTH)
- trophoblastic tumors (chorionic gonadotropin): hydatidiform mole, choriocarcinoma
- disseminated thyroid cancer
- **Struma ovarii**- toxic adenoma in an ovarian dermoid tumor

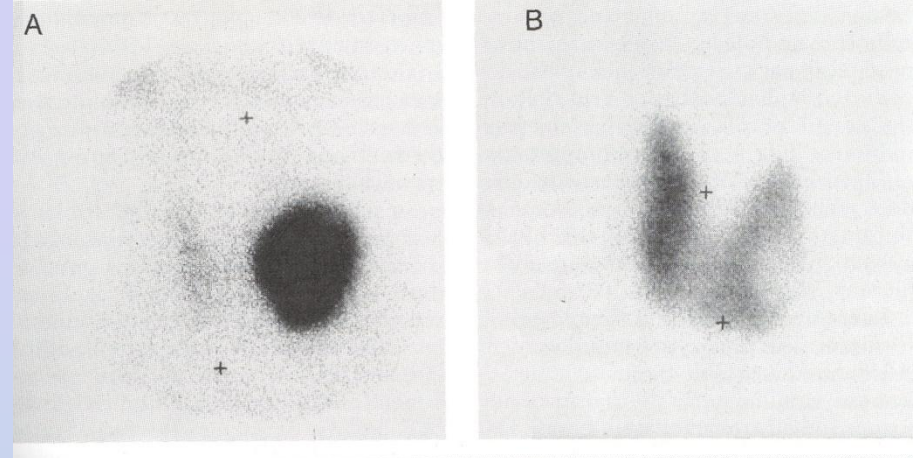
Toxic adenoma



Toxic adenoma

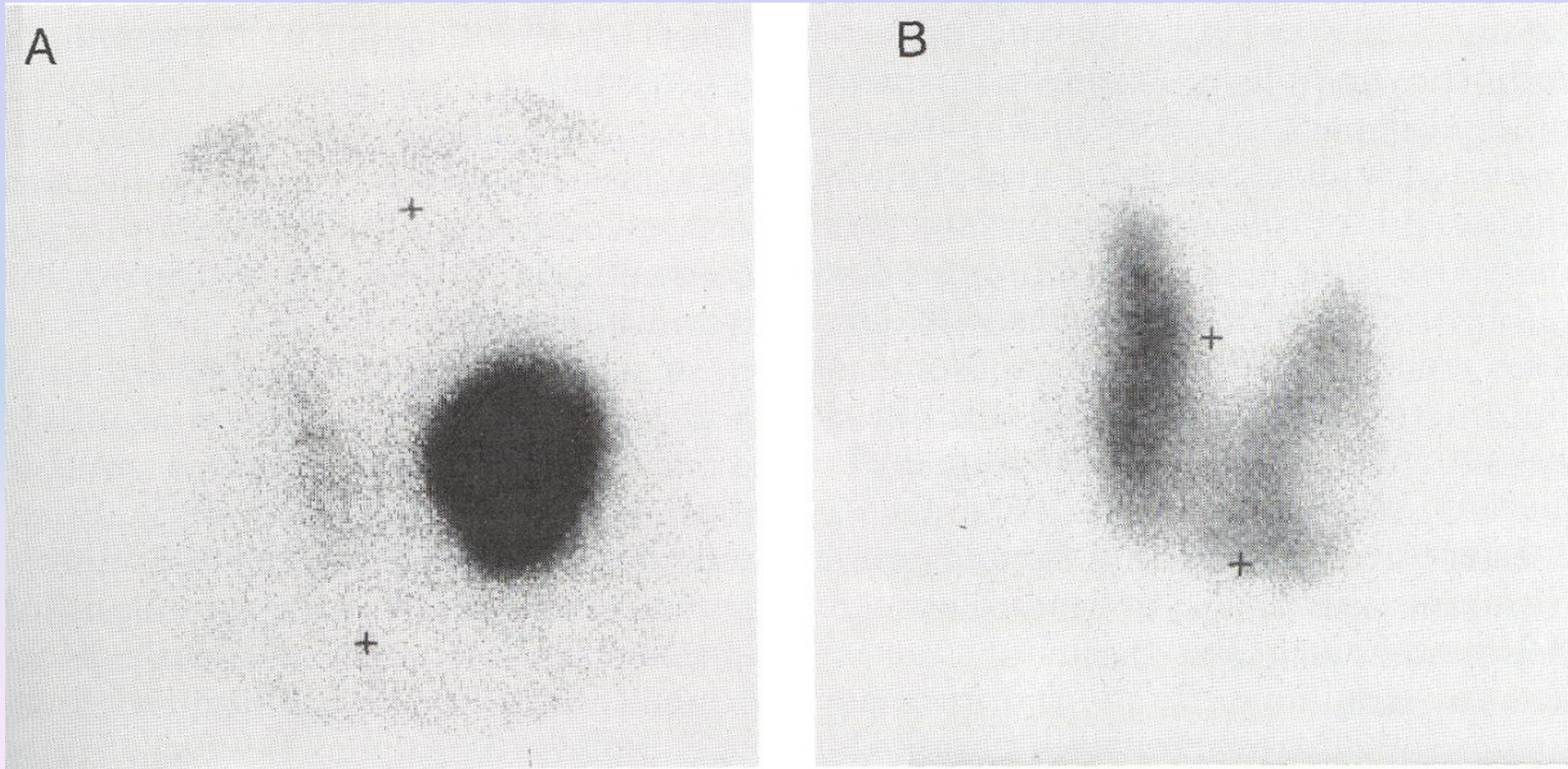
- Young and middle age
 - symptoms of hyperthyroidism
 - predominantly nervousness and cardiac symptoms
 - elevated T3 and T4, TSH suppression
 - scintigraphic „warm” nodule, the rest of the gland is invisible (suppressed)

Toxic adenoma



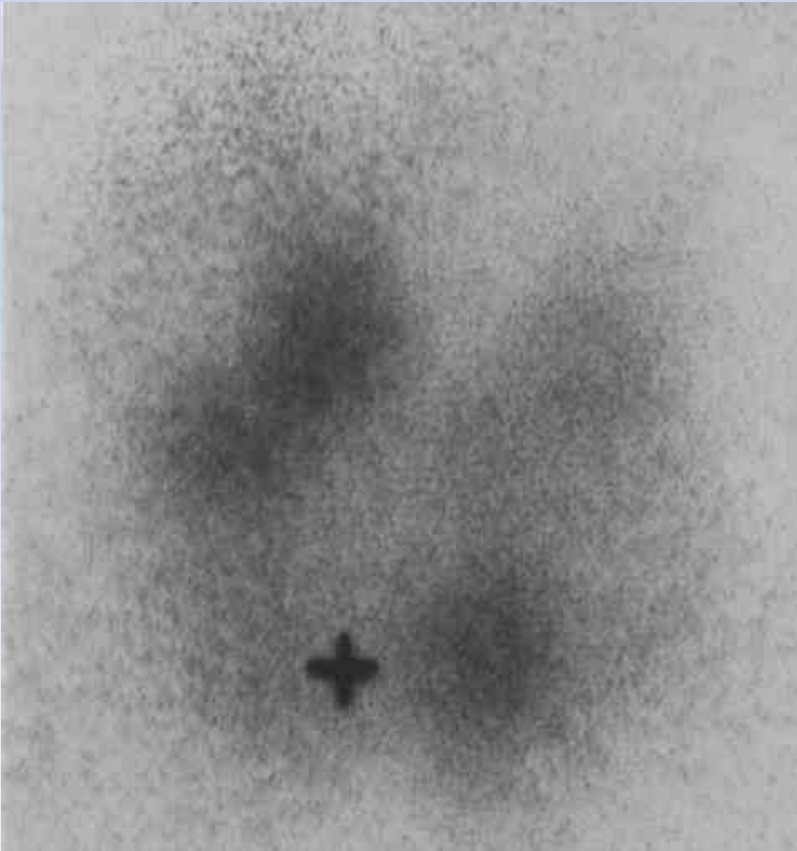
Slika 2-8. Toksični adenom: A = prije liječenja, B = nakon izlječenja radioaktivnim jodom.

- persistent hyperthyroidism
- long-term treatment with thyrostatic drugs is not indicated
- optimal treatment is radioactive iodine therapy (I-131)- efficacy 100%, hypothyroidism in 5%
- Activity in the nodule: 15 mCi (555 MBq)
- Activity per gram: 200-400 $\mu\text{Ci/g}$ (7,4-14,8 MBq)
- AD: 400 Gy per nodule
- Alternative: lobectomy or permanent thionamide therapy

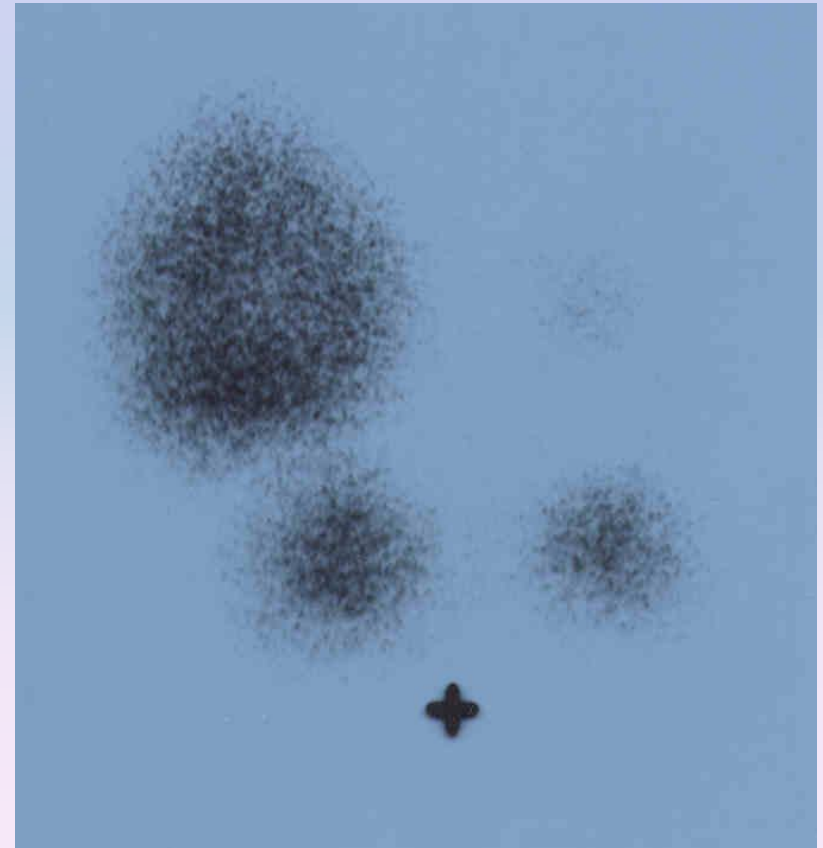


Toxic adenoma before I-131 treatment (A) and after (B)

Toxic multinodular (polynodular) goiter



Multinodular goiter
 ^{99m}Tc scintigraphy



Multinodular toxic goiter
 ^{131}I scintigraphy

Toxic multinodular goiter

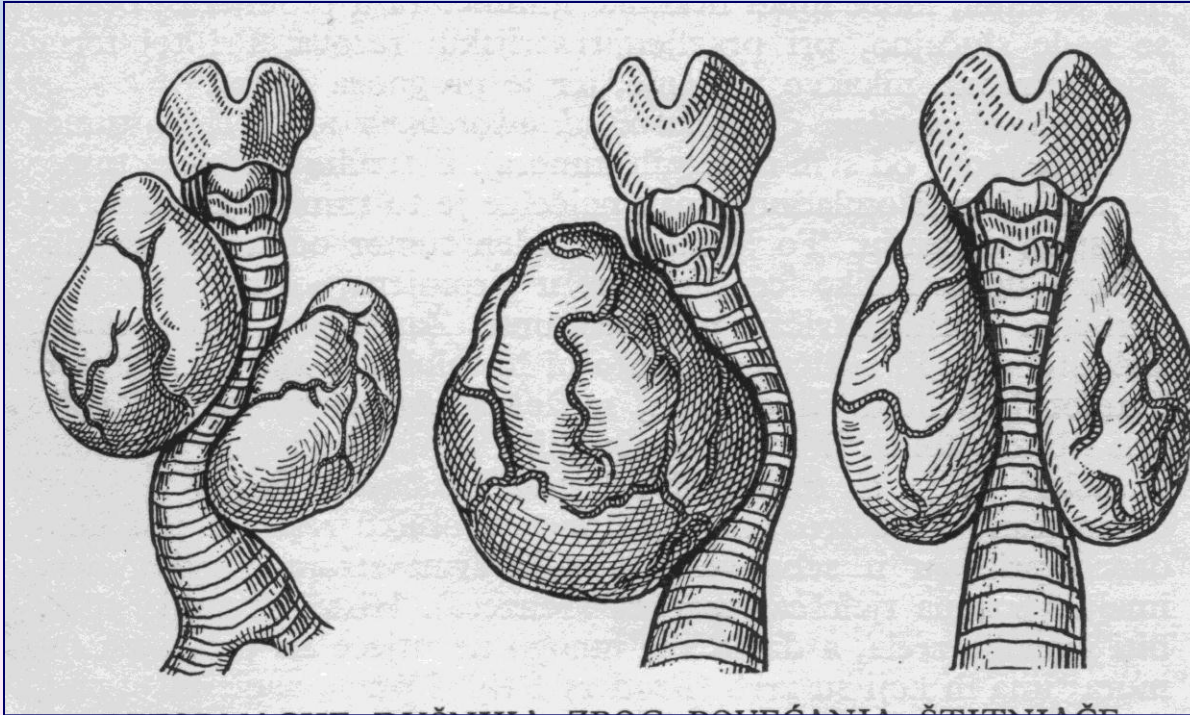
- persistent hyperthyroidism
- long-term treatment with thyrostatic drugs is not indicated
- optimal treatment is radioactive iodine therapy (I-131)- efficacy 100%, hypothyroidism in 5%
- activity per gram: 200-400 $\mu\text{Ci/g}$ (7,4-14,8 MBq)
- AD: 400 Gy
- alternative: total or subtotal thyreoidectomy or permanent thionamide therapy

Toxic multinodular goiter latent or subclinical hyperthyroidism

- TSH<0,1; T3 & T4 in normal range: I-131 is optimal therapy choice
- elevated thyroid hormone levels- in elderly thyrostatic therapy during 3-5 weeks, then I-131
- if thyrostatic therapy lasts during several years- thyrostatic drugs must be excluded 4 weeks before I-131 therapy

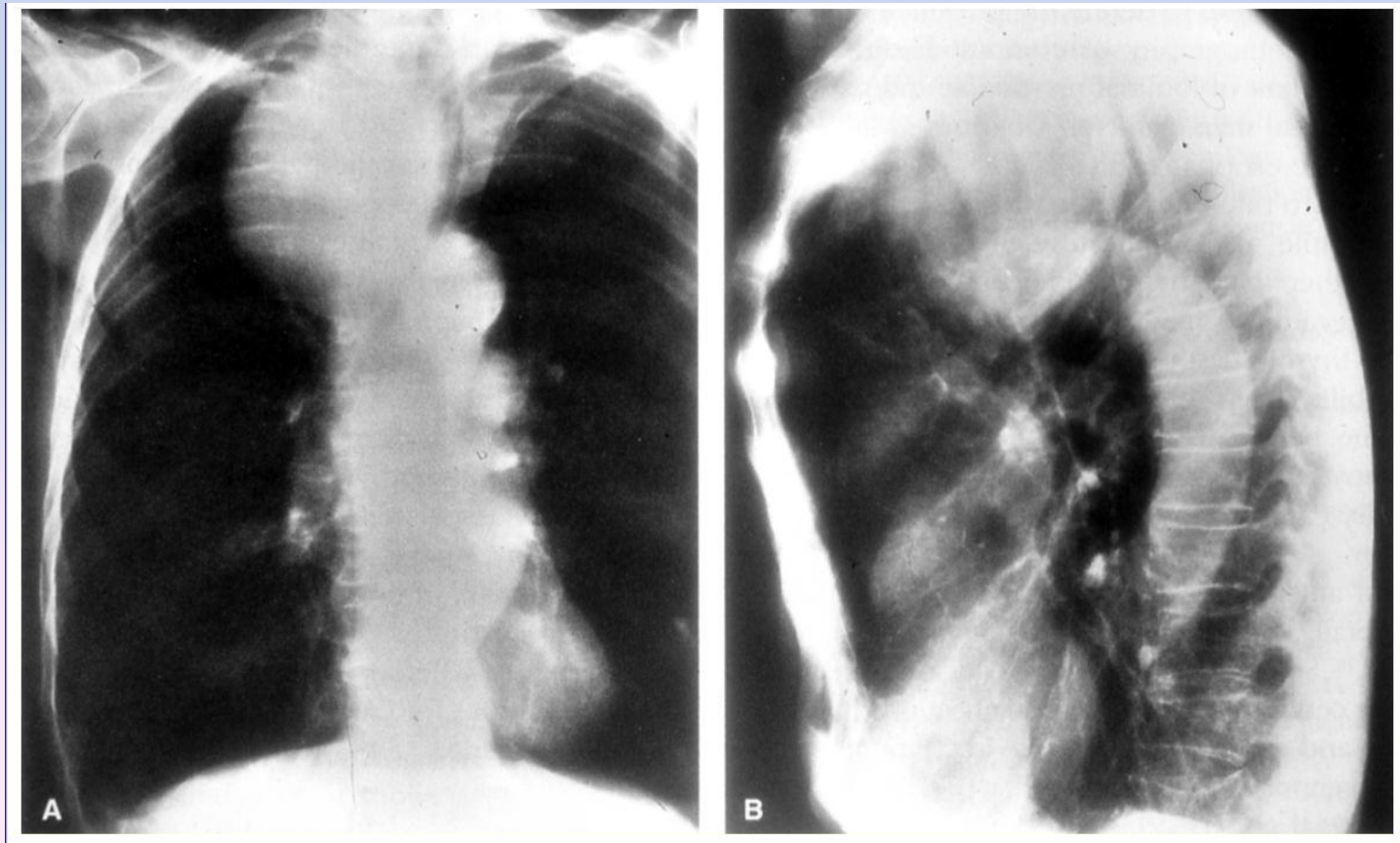
Toxic multinodular goiter

tracheal deviation, stenosis or
tracheomalation



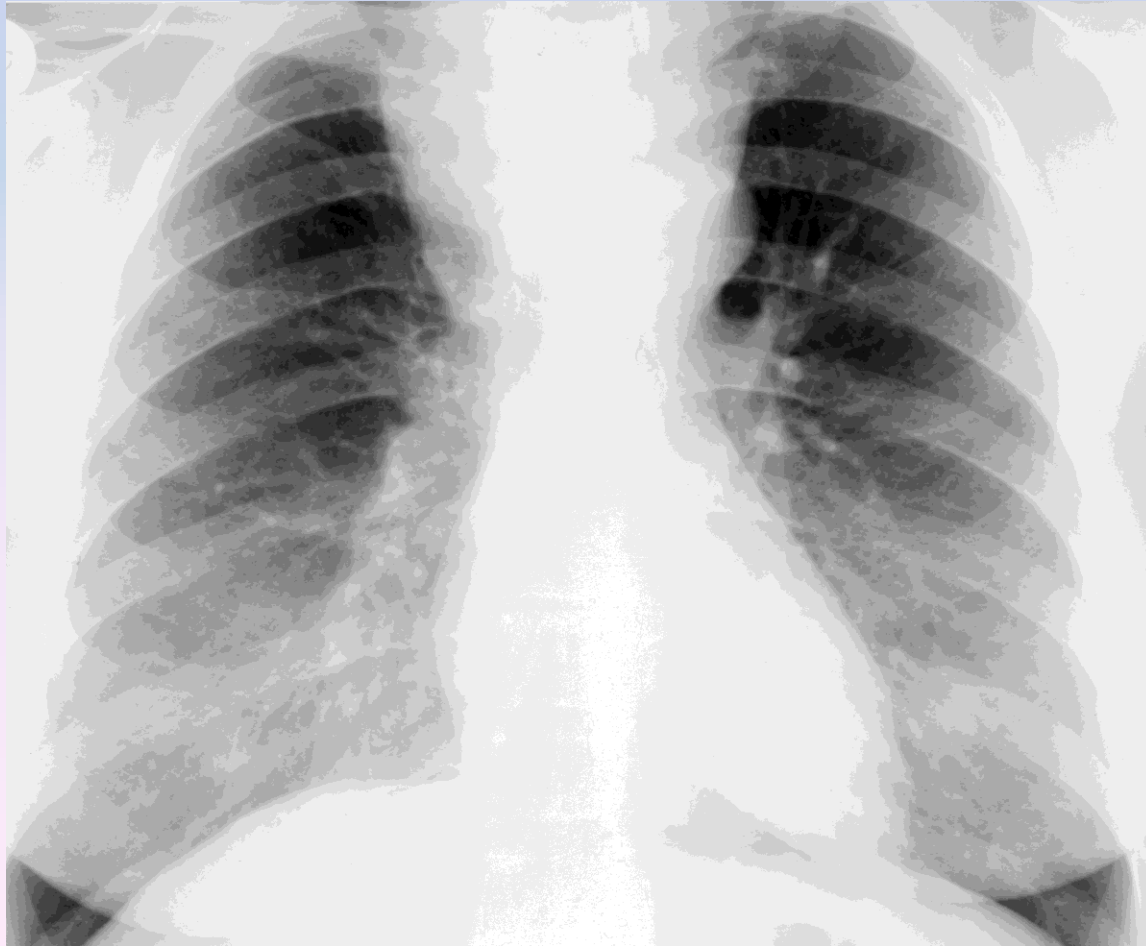
Toxic multinodular goiter

Substernal goiter



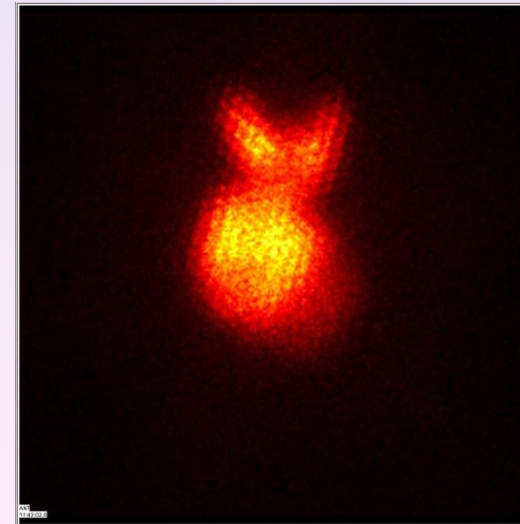
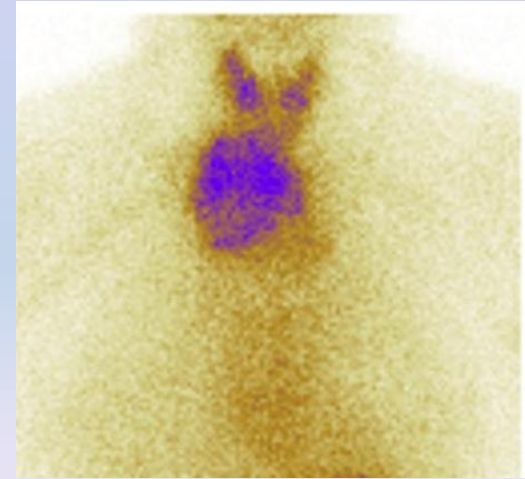
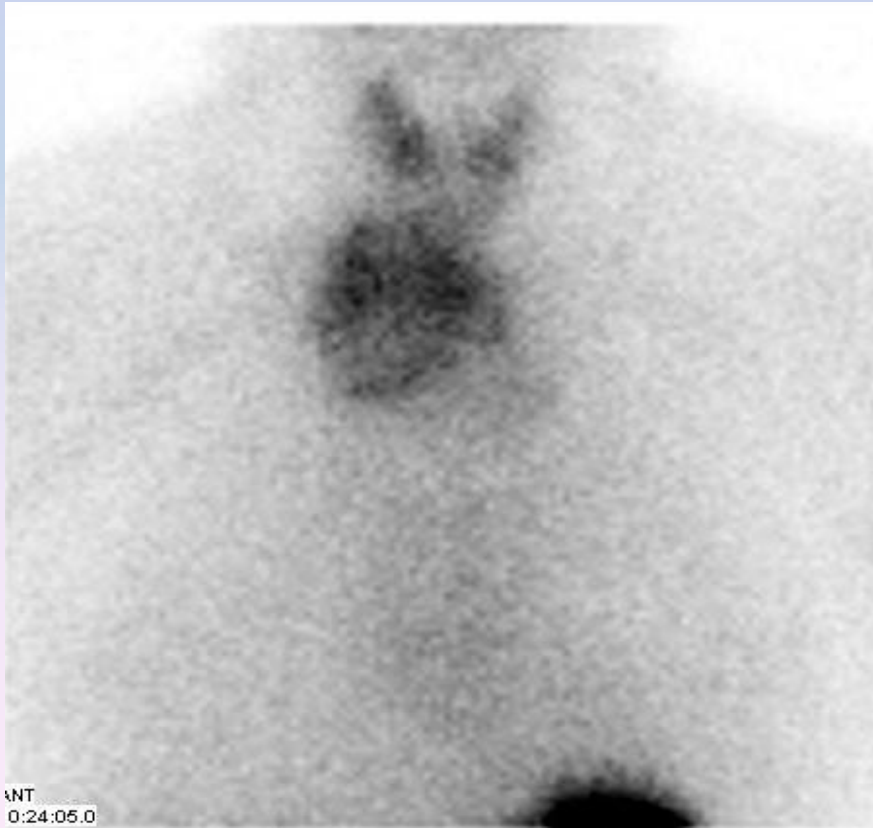Toxic multinodular goiter

Substernal goiter

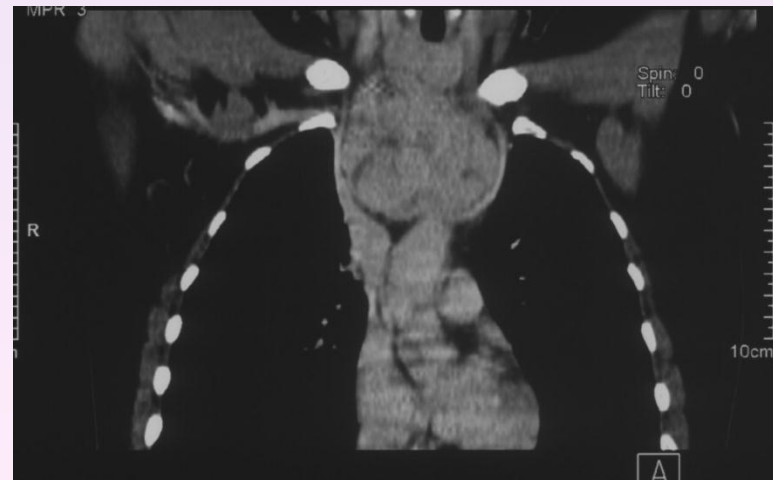
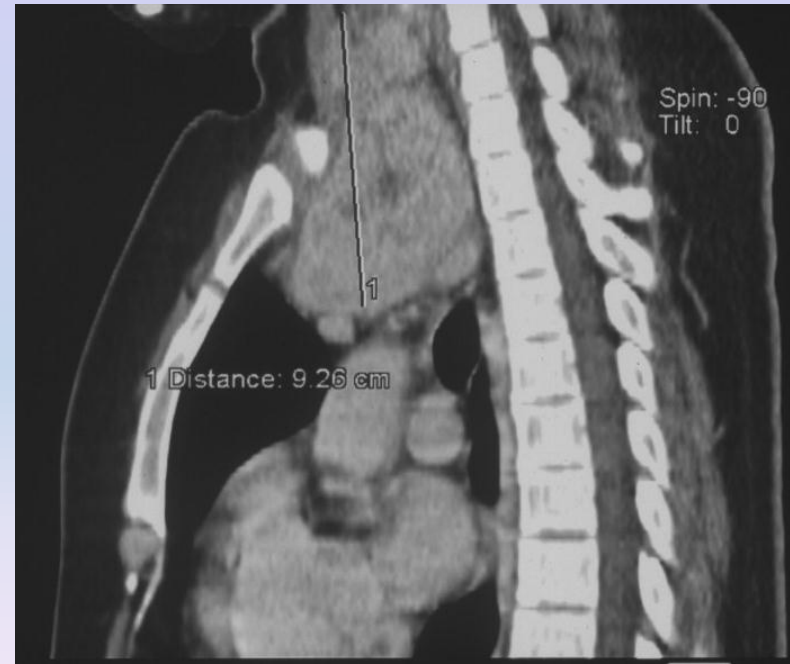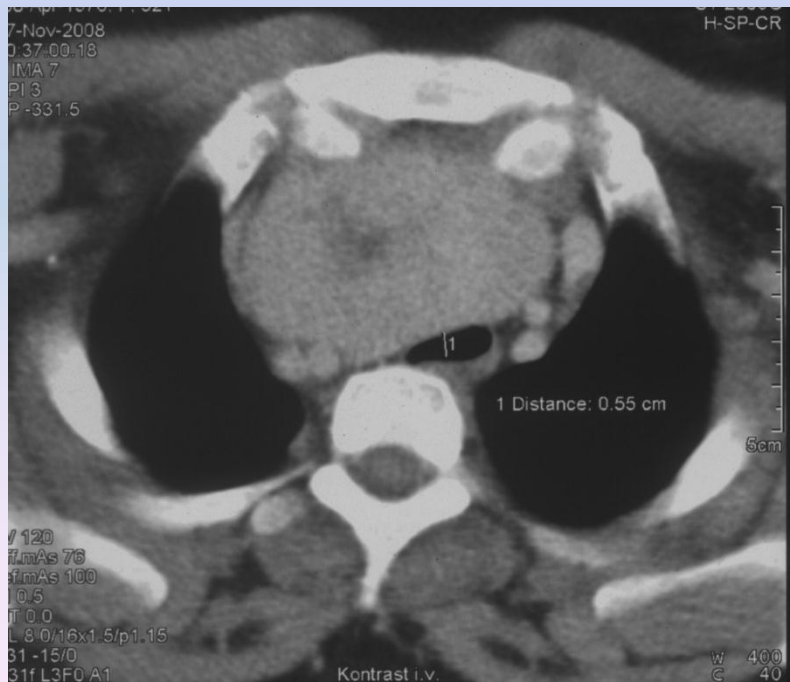


Toxic multinodular goiter

Substernal goiter



Toxic multinodular goiter



Jod-Basedow

- Hyperthyroidism caused by excessive intake of iodine (commonly antiarrhythmic agent- amiodarone). Usually there is a history of thyroid disease: thyroid autonomy or multinodular goiter

TABLE 1. COMMONLY USED IODINE-CONTAINING DRUGS

| <i>Drugs</i> | <i>Iodine content</i> |
|-----------------------------------------------------------------|---------------------------|
| Oral or Local | |
| <u>Amiodarone</u> | 75 mg tablet |
| <u>Benziodarone</u> ^a | 49 mg/100-mg tablet |
| Calcium iodide (e.g., Calcidrine syrup) | 26 mg/mL |
| Diiodohydroxyquin (e.g., Yodoxin) | 134 mg/tablet |
| Echothiophate iodide ophthalmic solution (e.g., Phospholine) | 5–41 µg/drop |
| Hydriodic acid syrup | 13–15 mg/mL |
| Iodochlorhydroxyquin (e.g., Entero-Vioform) | 104 mg/tablet |
| <u>Iodine-containing vitamins</u> | 0.15 mg/tablet |
| Iodinated glycerol (e.g., Organidin, ^b Iophen) | 15 mg/tablet 25 mg/mL |
| Idoxuridine ophthalmic solution (e.g., Herplex) | 18 µg/drop |
| Isopropamide iodide (e.g., Darbid, Combid) | 1.8 mg/tablet |
| Kelp | 0.15 mg/tablet |
| <u>Potassium iodine (KI)</u> (e.g., Quadrinal) | 145 mg/tablet 24 mg/mL |
| <u>Lugol's solution</u> | 6.3 mg/drop |
| Niacinamide hydroiodide + KI (e.g., Iodo-Niacin) | 115 mg/tablet |
| Ponaris nasal emollient | 5 mg/0.8 mL |
| <u>SSKI</u> | 38 mg/drop |

Parenteral preparations

Sodium iodide, 10% solution 85 mg/mL

Topical Antiseptics

Diiodohydroxyquin cream (e.g., Vytone) 6 mg/g
Iodine tincture 40 mg/mL
Iodochlorhydroxyquin cream (e.g., Vioform) 12 mg/g
Iodoform gauze (e.g., NuGauze) 4.8 mg/100 mg gauze
Povidone iodine (e.g., Betadine) 10 mg/mL

Radiology contrast agents

Diatrizoate meglumine sodium
(e.g., Renografin-76) 370 mg/mL
Iodized oil 380 mg/mL
Iopanoic acid (e.g., Telepaque) 333 mg/tablet
Iodate (e.g., Oragrafin) 308 mg/capsule
Iothalamate (e.g., Angio-Conray) 480 mg/mL
Metrizamide (e.g., Amipaque) 483 mg/mL
before dilution

^aNot FDA approved.

^bIodine was removed from Organidin and Tuss Organidin in 1995


(Adapted from Braverman LE 1986 Iodide-induced thyroid disease. In: Ingbar SH, Braverman LE (eds) Werner's The Thyroid, 5th ed. Philadelphia, JB Lippincott, p 734.)

Amiodarone!

10% of patients have symptoms of hyperthyroidism

Hypothyroidism occurs in 15-20%

Supervision- check thyroid hormone level every three weeks!



Interferon- α -Related Thyroid Disease: Pathophysiological, Epidemiological, and Clinical Aspects

Adverse effects of IFN treatment include systemic and organ-specific pathological changes, many of them being the consequences of immune enhancement or immune dysregulation induced by IFN itself (10–12). The main effect of IFN α on the immune system is the enhancement of cell cytotoxicity, which is important for antineoplastic and antiviral activity (10). The stimulation of cytotoxicity is mainly due to an up-regulation of perforin expression in peripheral natural

In patients treated with IFN, activation of the immune system is important for the development of thyroid disease. Furthermore, IFN has direct inhibitory effects on thyroid hormone synthesis, release, and metabolism (24–26). The

Trophoblastic tumors

- Presence of chorionic gonadotropin (HCG)-
it has same α -subunit as TSH, LH and FSH
so it can stimulate thyroid gland
 - hydatidiform mole
 - choriocarcinoma

Hyperthyroidism with elevated TSH

- Pituitary adenoma
- TRH – stimulation – hypothalamus
- Pituitary resistance to thyroid hormone (loss of negative feedback)

Thyrotoxic crisis (thyroid storm)

- Extreme thyrotoxicosis, hyperpyrexia, agitation
- In case of untreated hyperthyroidism, it may be induced by surgery treatment, infection, trauma or cerebrovascular insult.
- Therapy: plasmapheresis, thyrostatic drugs, beta-blockers, corticosteroids, lithium, iodide, supportive treatment

Thyrotoxicosis without hyperthyroidism

- Thyroid inflammation
- Factitious thyrotoxicosis (thyrotoxicosis medicamentosa)
- Ectopic thyroid tissue
 - struma ovarii
 - disseminated well differentiated thyroid cancer

Inflammation of the thyroid gland

(acute, subacute, chronic)

- 1. Subacute thyroiditis (De Quervain)**
- 2. Lymphocytic thyroiditis** (with or without goiter – Hashimoto's)
- 3. Postpartal thyroiditis**
4. Chronic fibrous thyroiditis (Riedel's)
5. Acute thyroiditis (in children)
6. Specific inflammations (TBC, syphilis)
7. Radiation-induced thyroiditis
8. Iodine or interferon induced thyroiditis

Thyroiditis- clinical presentation

a) **Acute thyroiditis**

high fever, painful swelling in the lower neck with skin redness

b) **Subacute thyroiditis:**

pain in the neck spreading to the ear, increased erythrocyte sedimentation rate (ESR), high fever, swollen and painful thyroid, symptoms of thyrotoxicosis

c) **Chronic thyroiditis**

usually without symptoms, stiffer and enlarged thyroid gland, but may be normal in size or even smaller, during some time patients may develop hypothyroidism

Thyroiditis- clinical presentation

d) **Subacute silent thyroiditis**, usually occurs after delivery (postpartum thyroiditis)

Clinical manifestations of thyrotoxicosis, with no pain, fever or increased erythrocyte sedimentation rate (ESR)

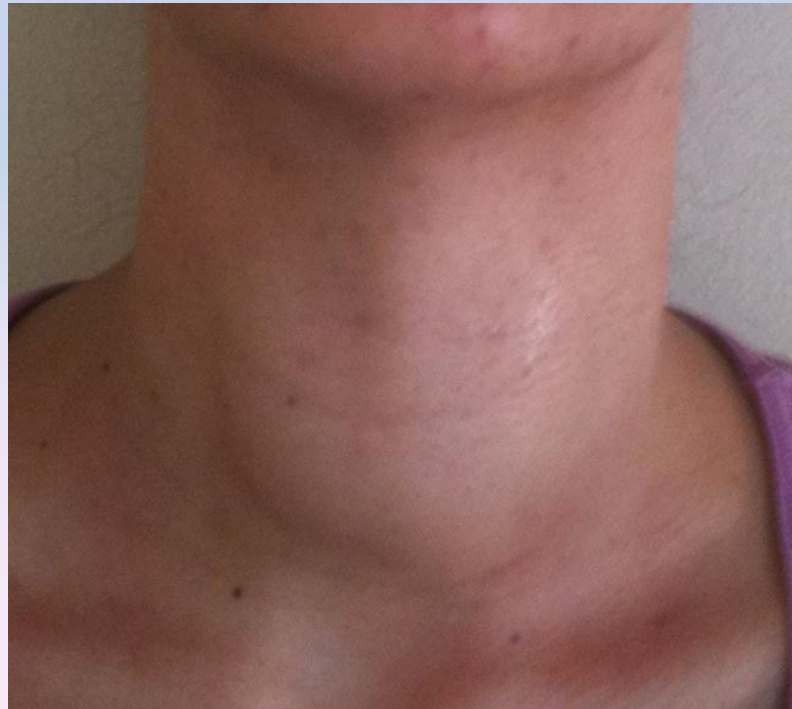
Treatment of hyperthyroidism and thyrotoxicosis

Diffuse toxic goiter treatment

Medicamentous

Surgical

I-131



Medicamentous treatment

- **thionamides**
- **beta-adrenergic blocking agents (temporarily)**
- **thiocyanate and perchlorate**
- **lithium carbonate**
- **stable iodine (I-127)**
- **corticosteroids**

Thionamides

- **methimazole**, carbimazole
- **propylthiouracil**
- Activity :
 - **intrathyroidal**
 - extrathyroidal
 - immune system: lymphocyte infiltration,
antibody levels

Radioiodine therapy (RIT, I-131) of diffuse toxic goiter

- It is considered as the best, the safest, the simplest and the cheapest therapy for most of the patients

but...

There are three forms of RIT

- Fixed activity over thyroid
- Activity per gram of thyroid
- Thyroid absorbed dose

The aim of RIT

- **The ideal aim is eutyroidism**

But so far there is no way to calculate individual dose for each patient, and the mentioned ideal aim can not be reached in a satisfactory percentage

- According to that reason, hypothyroidism after RIT is accepted as favorable treatment outcome

- *So, there are two modalities of RIT, according to clinical evaluation and patient preference:*
 - *high activity, **ablative dose***
 - *low activity, **non ablative dose***

RIT

- **Ablative therapy:** aim is the most safer treatment of hyperthyroidism, which mainly leads to permanent hypothyroidism
- **Non ablative therapy:** the aim is to achieve **euthyreoidism**, **avoiding permanent hypothyroidism**, resulting in higher percentage of persistent hyperthyroidism which requires re-treatment

Author

Fixed activity

| | MBq (mCi) |
|--------------------|-------------------------------------------|
| Watson et al. | 185 (5) |
| Allahabadia et al. | 185, 370 (5, 10) |
| Esfahani et al. | 185, 370 (5, 10) |
| Franklyn et al. | 111, 185, 370, 555 (3, 5, 10, 15) |
| Nordyke et al. | 111, 144, 185, 212, 296, 370 (3-6, 8, 10) |
| Jarlov et al. | 185, 370, 555 (5, 10, 15) |

Author

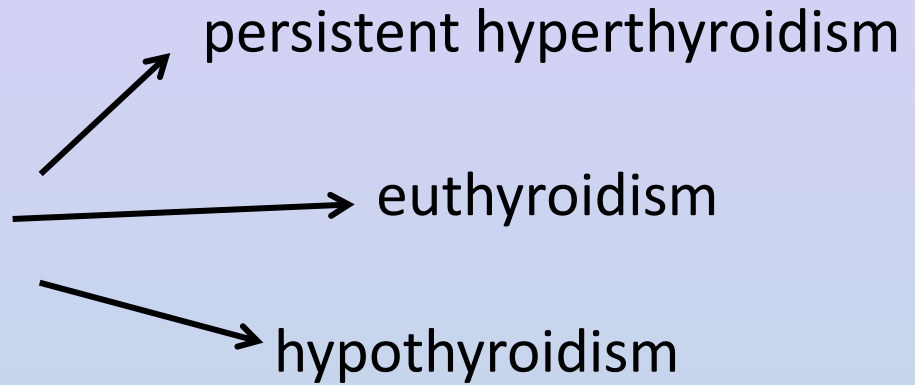
Activity per gram of thyroid MBq/g (μ Ci/g)

| | |
|-----------------|------------------------|
| De Bruin et al. | 3,7 (100) |
| Chen et al. | 3,7 (100) |
| Leslie et al. | 2,96 i 4,44 (80 i 100) |
| Veliz et al. | 4,44 (100) |
| Chiovato et al. | 7,4 (200) |

•Thyroid absorbed dose!

What is the problem?

→ Same AD- different outcomes



→ Same AD- different outcomes from various authors???!!!

150 Gy

persistent hyperthyroidism (%)

Grosso M et al.

15

Pfeilschifter et al.

30

Zophel et al.

63

Wide range of AD were applied

from 50 - >300 Gy

AD (Gy)

Author

| | |
|------------------|----------------|
| Catargi et al. | 50 |
| Howarth et al. | 60, 90 |
| Bajnok et al. | 70 |
| Nagayama et al. | 80 |
| Peters et al. | 100 |
| Berg et al. | 100, 120 |
| Haase et al. | 150, 220, 260 |
| Reinhardt et al. | 150, 200, 300 |
| Sabri et al. | 200, 250 |
| Grosso et al. | 150, 300, >300 |
| Willemsen et al. | 300 |

0021-972X/07/\$15.00/0

Printed in U.S.A.

The Journal of Clinical Endocrinology & Metabolism 92(9):3547-3552

Copyright © 2007 by The Endocrine Society

doi: 10.1210/jc.2007-0879

Thyroid Echogenicity Predicts Outcome of Radioiodine Therapy in Patients with Graves' Disease

Vinko Marković and Davor Eterović

Department of Nuclear Medicine (V.M., D.E.), University Hospital Split, 21 000 Split, Croatia; and Department of Medical Physics and Biophysics (D.E.), Split University School of Medicine, 21 000 Split, Croatia

J Nucl Med 2008; 49:2026–2030

DOI: 10.2967/jnumed.108.053934

**Planning of ¹³¹I Therapy for Graves Disease Based
on the Radiation Dose to Thyroid Follicular Cells**

*Davor Eterović^{1,2}, Željko Antunović³, Vinko Marković¹, and
Darko Grošev⁴*

J Nucl Med • 2009; Vol. 50 • No. 5

**¹³¹I Radiation Dose Distribution in Metastases of
Thyroid Carcinoma**

Davor Eterović, Vinko Marković, Ante Punda and Željko Antunović
University of Split, Split, Croatia

Eur J Nucl Med Mol Imaging (2009) 36:721–722.

Determinants of ¹³¹I radiation dose to thyroid follicular cells

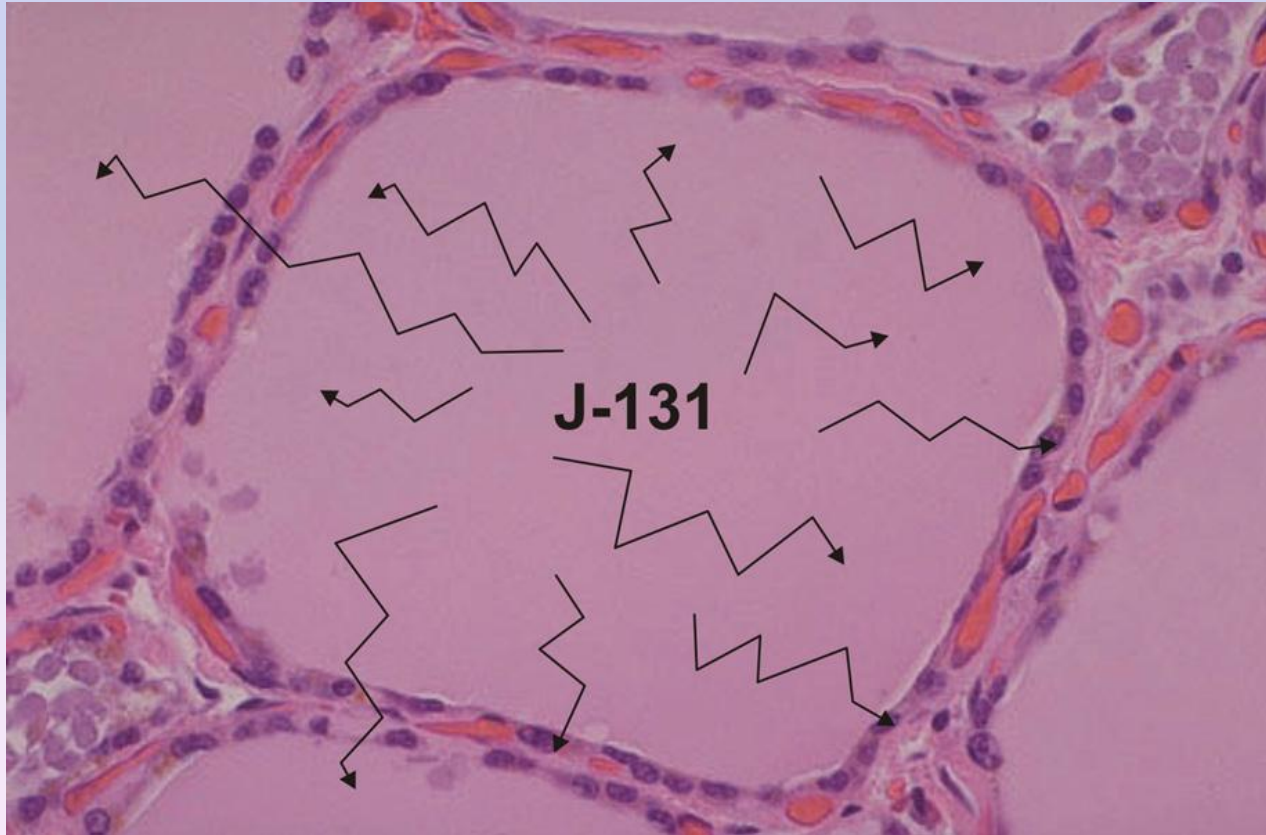
Davor Eterović, Vinko Marković, Željko Antunović and Ante Punda

Medical Hypotheses 76 (2011) 153–156

Thyroid echogenicity: A clue to precise individual dosimetry in radioiodine therapy of hyperthyroidism

V. Marković, D. Eterović, P. Stipanović, A. Punda.

→ Irradiation of cellular structures would lead to biological effects, while energy deposited in colloid have no biological effect

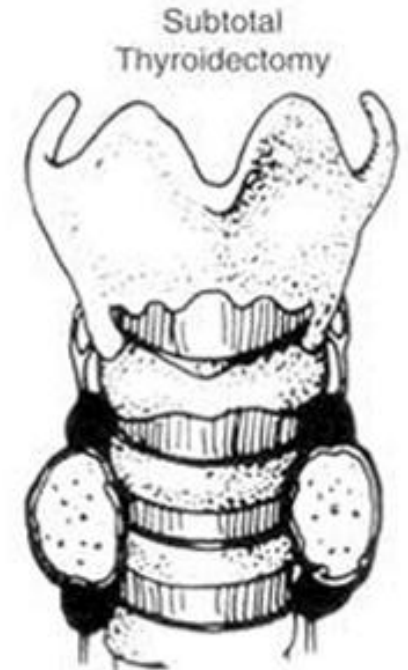


→ Percentage of beta particles emitted from I-131 that will be absorbed in colloid (so they would not reach follicular cells) depends on size of follicles

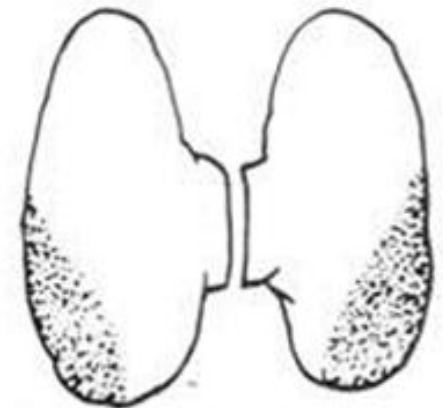
Surgical treatment

Subtotal thyroidectomy: if there is residual tissue (small amount, in grams) in bed of each lobe:

- 5-15% hyperthyroidism relapse
- 2-80% hypothyroidism



FOR



Graves' disease
(diffuse toxic goiter)

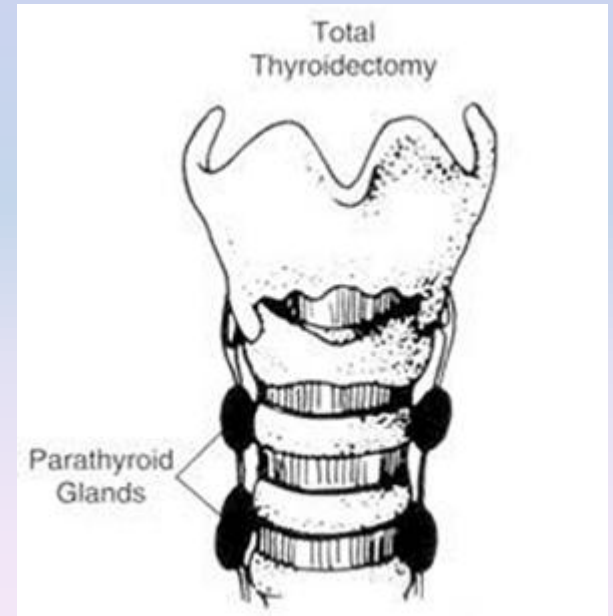
Surgical treatment

Total or subtotal thyroidectomy

- 100% hypothyroidism

Complications: 1-2% hypoparathyroidism
and paresis of n. recurrens

**Indicated only if I-131 therapy is not
the treatment option**



Clinical approach in diffuse toxic goiter treatment

- goal of medicamentous therapy (up to 2 yr.) is keeping eumetabolic state while waiting for remission - 50% pts.
- other 50%: I-131 or surgical treatment
- the main determining factors :
 - age
 - clinical state
 - size of the thyroid gland

- **Children and adolescents:** subtotal or almost total thyroidectomy
- **Young adults (18-30 yr.)**
 - non ablative dose of I-131
 - huge gland (> 100 grams): subtotal or almost total thyroidectomy
- **Adults:** I-131 is therapy of choice
 - generative age: non ablative I-131 dose
 - elderly, thyrotoxic heart: ablative I-131 dose
 - huge gland (> 100 grams): almost total thyroidectomy
- **Severe ophthalmopathy:** total thyroidectomy
- **Allergic reaction to thyrostatic drugs:** I-131 or almost total thyroidectomy

**Pregnancy- thionamides: PTU first trimester,
methimazole other two trimesters**

Breastfeeding- PTU? methimazole?

Interrupt (quit) breastfeeding and start
thyrostatic therapy

Thyroiditis treatment

1. Acute thyroiditis

- antibiotic, antipyretics, analgesics
- surgical incision

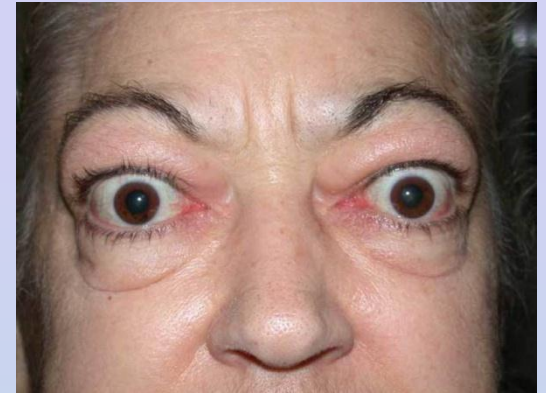2. Subacute thyroiditis

- symptomatic: beta-blockers; painfull- antipyretics, analgesics, corticosteroids

3. Chronic thyroiditis

- levothyroxine substitution therapy in hypothyroidism

Ophthalmopathy treatment



1. general: protective glasses, elevated pillow, artificial tears, diuretics
2. corticosteroides: retrobulbar, parenteral irradiation of eye orbit
3. immunosuppressive therapy
4. surgical treatment (orbital decompression, removal of fat tissue..)

The end!